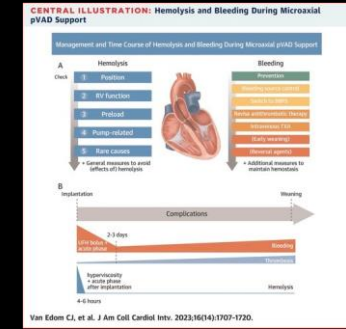
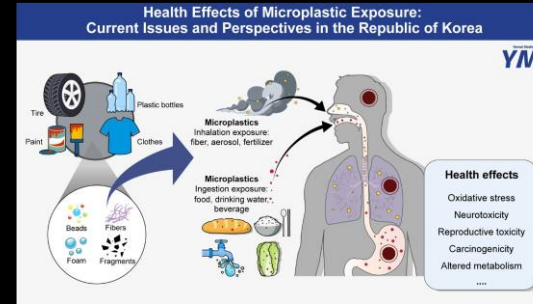
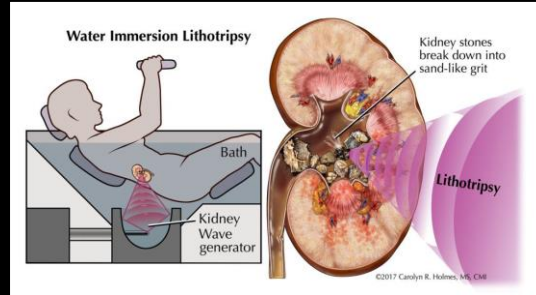
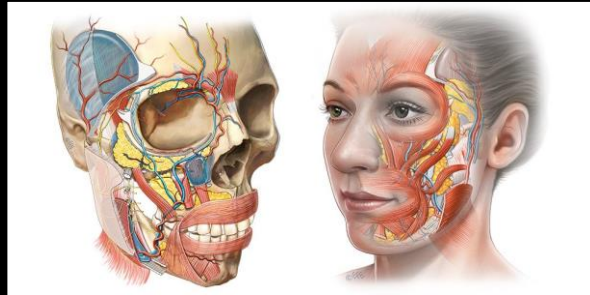


논문 작성을 위한 *Figure* 및
Graphic Abstract 정리방법
(*adobe* 프로그램 중심으로)

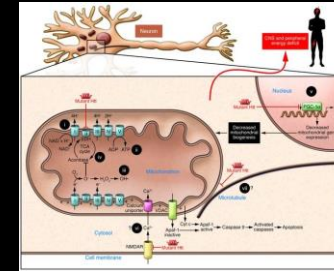
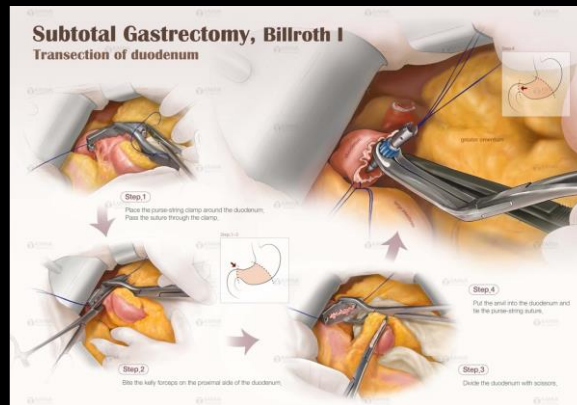
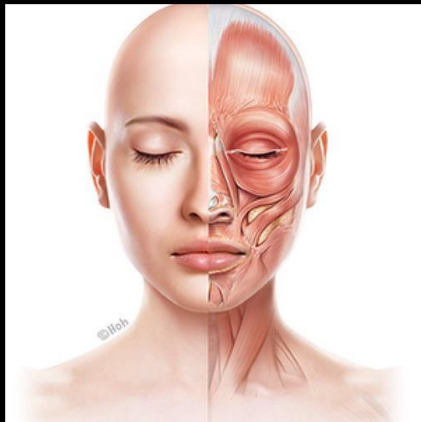장 동수
Medical Illustrator

의학그림

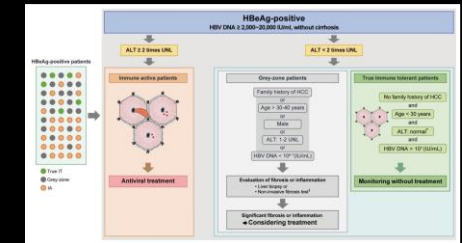


Graphical abstracts

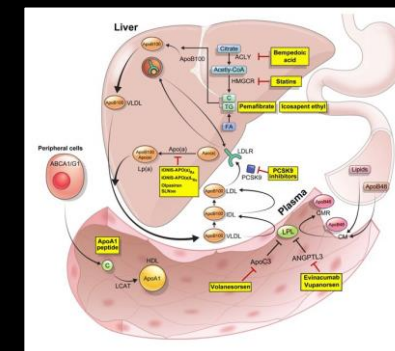
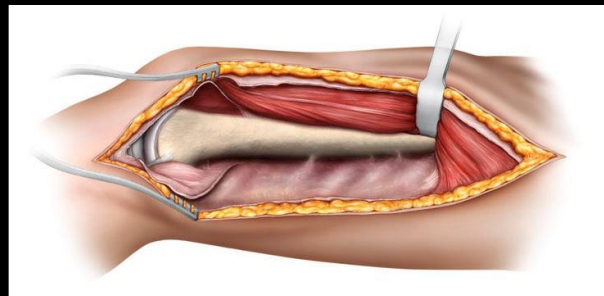
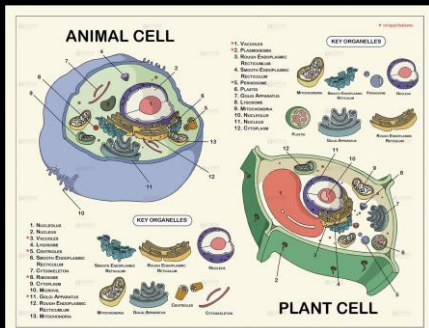
Central Illustration



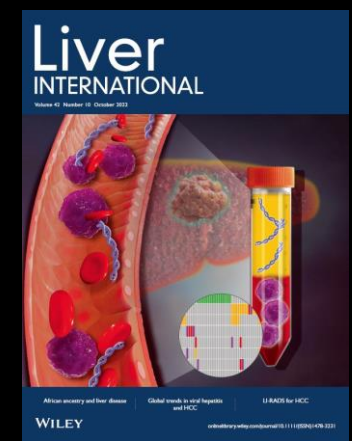




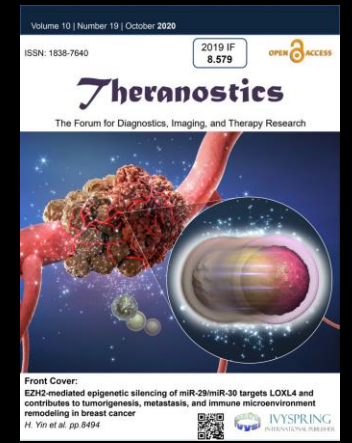
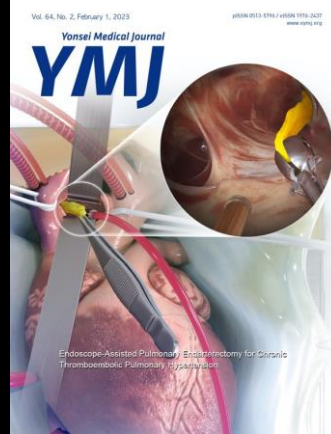


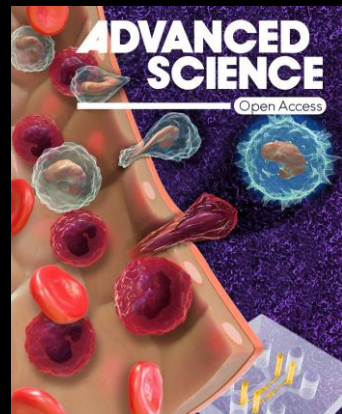


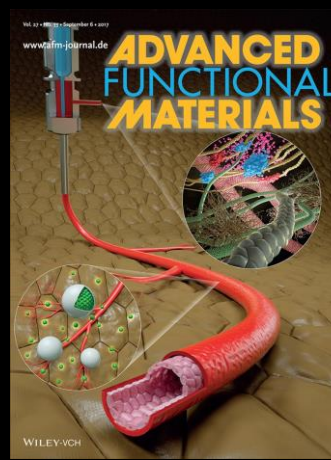
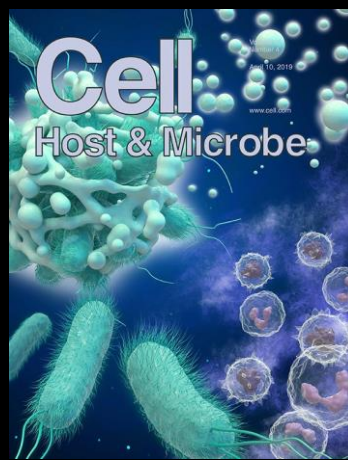
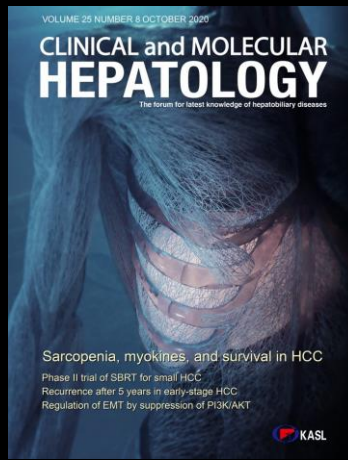
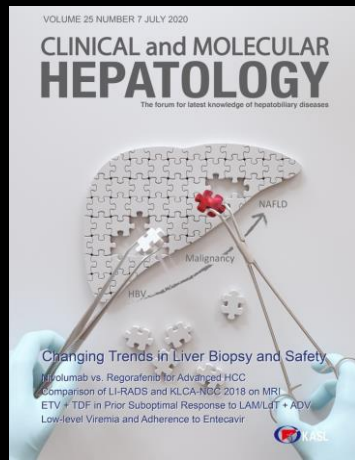

Summary Figure



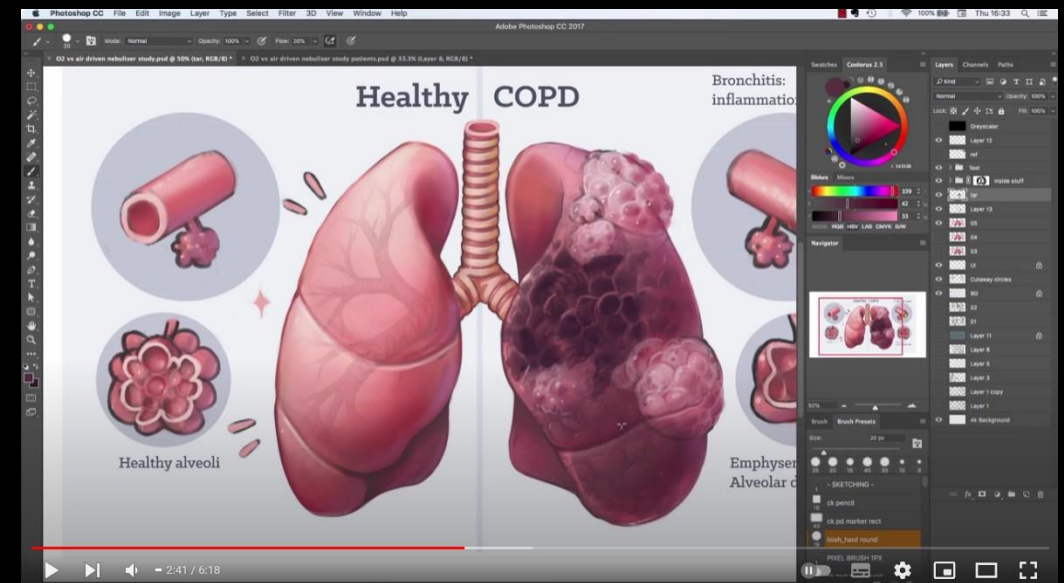
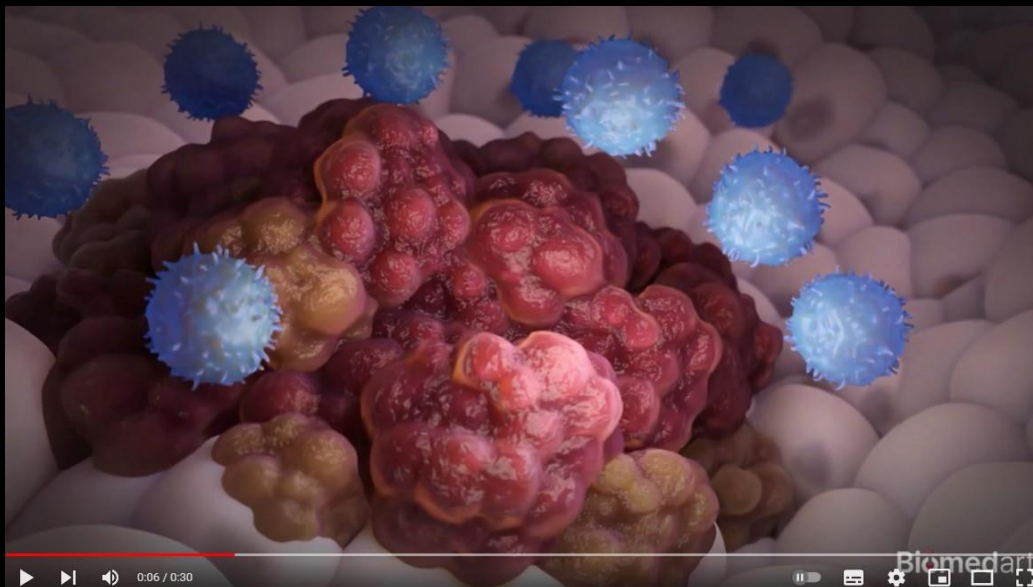
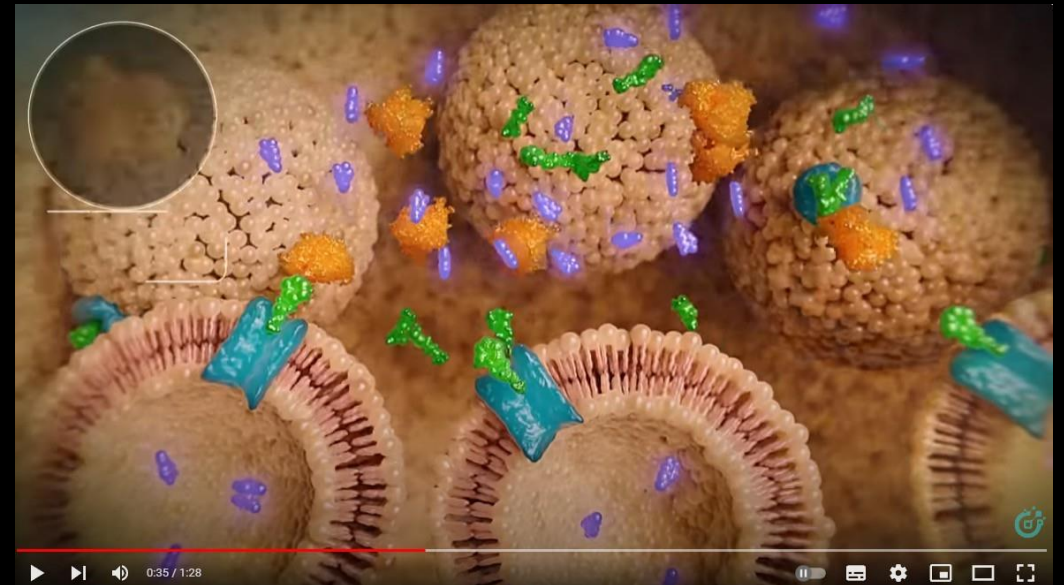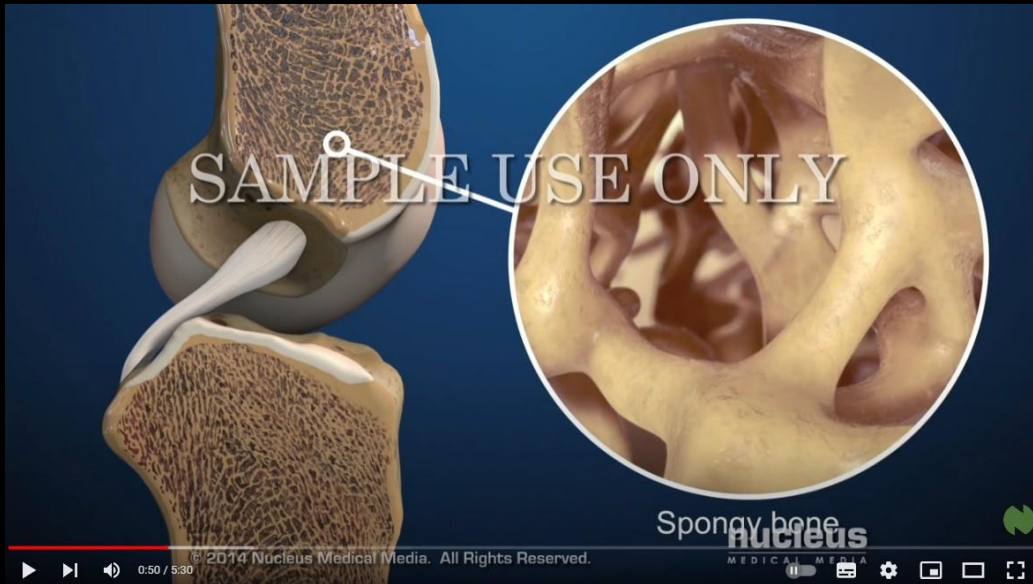Snapshot



Key Figure



영상제작





Design- thinking



공감



정의



아이디어



프로토타입



테스트

Figure 정리 방법

- Figure types 구분
- Photoshop, Illustrator 차이
- RGB 와 CMYK 구분
- 꼭 필요한 Illustrator 메뉴 확인
- SPSS 그래프 추출하는 방법
- R 그래프 추출하는 방법
- embed/ Ai 이미지포함
- Clipping Mask 기능 및 Align Figure 크기와 논문형식에 맞춰
- Artboards 크기조절
- Tiff, eps 또는 PDF 변환

Graphical abstract 제작방법

- Graphical Abstract 유형
- GA 필요한 콘티 설정하는 방법
- Adobe Illustrator Tool익히기 (그림관련 Tool)
- 사진 또는 밑그림을 활용한 그림 그리는 방법
- library 를 활용한 이미지 제작방법
- 통계(SPSS, R, Prism) vector 추출방법
- Target 저널 유형에 맞춰 이미지 추출방법

Graphical
Abstract 제작

Figure 제작





논문의 그래픽 초록 작업이 가능한 프로그램 추천 부탁드립니다.



논문이나 연구 논문의 그래픽 초록 작성은 다양한 그래픽 디자인 및 이미지 편집 소프트웨어를 사용하여 수행할 수 있습니다. 그래픽 초록을 디자인하는 데 사용할 수 있는 인기 있는 프로그램은 다음과 같습니다.



1. **Adobe Illustrator:** Adobe Illustrator는 복잡하고 상세한 일러스트레이션을 만드는 데 널리 사용되는 전문 벡터 그래픽 편집기입니다. 모양, 텍스트 및 색상을 정밀하게 제어해야 하는 경우 탁월한 선택입니다.



2. **Adobe Photoshop:** Photoshop은 이미지 및 그래픽 작업에 적합한 또 다른 Adobe 제품입니다. 래스터 기반이므로 이미지와 사진이 포함된 그래픽 추상에 가장 적합합니다.



3. **Canva:** Canva는 다양한 템플릿과 디자인 요소를 제공하는 사용자 친화적인 웹 기반 디자인 도구입니다. 광범위한 디자인 기술 없이도 눈길을 끄는 그래픽을 만드는 데 적합합니다.



4. **Inkscape:** Inkscape는 Adobe Illustrator와 유사한 무료 오픈 소스 벡터 그래픽 편집기입니다. 비용 없이 전문가 수준의 기능이 필요한 사람들에게 탁월한 선택입니다.



5. **GIMP(GNU 이미지 조작 프로그램):** GIMP는 Adobe Photoshop과 유사한 무료 오픈 소스 래스터 그래픽 편집기입니다. 이미지와 사진 작업을 위한 탁월한 선택입니다.



6. **Microsoft PowerPoint:** 간단하고 널리 액세스할 수 있는 옵션을 찾고 있다면 PowerPoint를 사용하여 그래픽 초록을 만들 수 있습니다. 기본 디자인 도구를 제공하며 대부분의 사람들이 액세스할 수 있습니다.

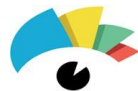

7. **Keynote(Mac 사용자용):** Keynote는 Apple의 프레젠테이션 소프트웨어로, macOS에서 그래픽 초록을 만드는 데 사용할 수 있습니다. 사용자 친화적이며 다양한 디자인 도구를 제공합니다.




8. **온라인 도구:** 그래픽 초록을 쉽게 만드는 데 도움이 되는 Piktochart, Visme, Crello와 같은 다양한 온라인 디자인 도구와 플랫폼이 있습니다. 이러한 도구는 종종 템플릿과 끌어서 놓기 기능을 제공합니다.

소프트웨어 선택은 도구에 대한 친숙도와 그래픽 초록에 대한 특정 요구 사항에 따라 달라집니다. 귀하의 필요에 맞는 프로그램을 선택할 때 복잡성 수준, 예산 및 설계 기술을 고려하십시오. 또한, 귀하의 연구를 제출하려는 기관이나 저널에서 제공하는 그래픽 초록에 대한 지침이나 형식 요구 사항을 따르는 것이 중요합니다.





AFFINITY
Designer2



CorelDRAW[®]
GRAPHICS SUITE



INKSCAPE




GIMP


유료 프로그램

무료 프로그램

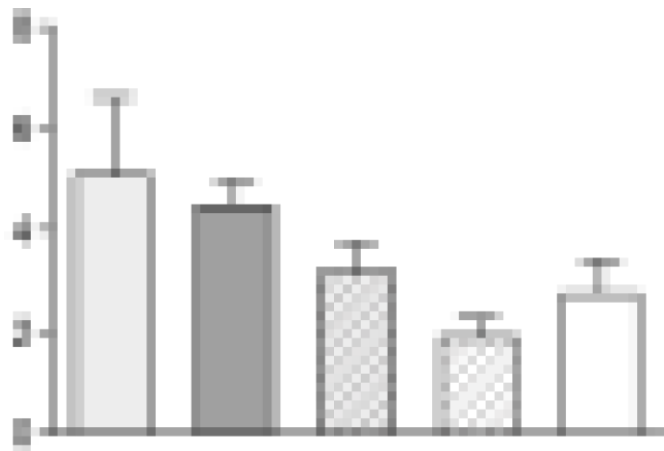
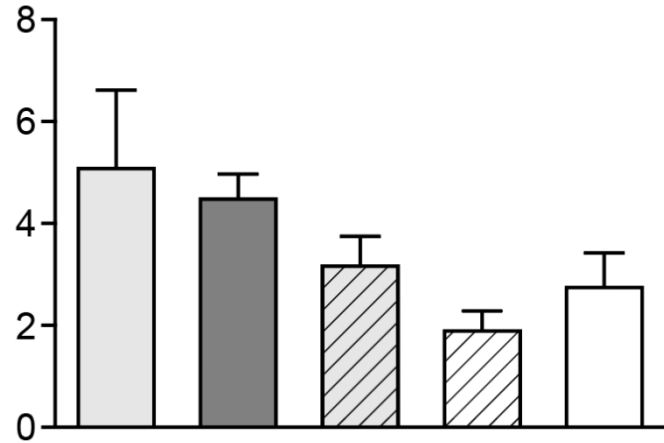
Raster Images (Bitmap)



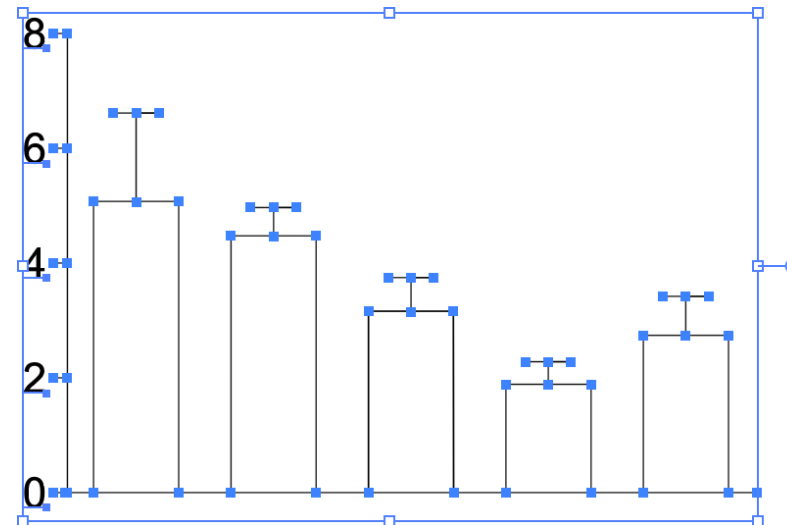
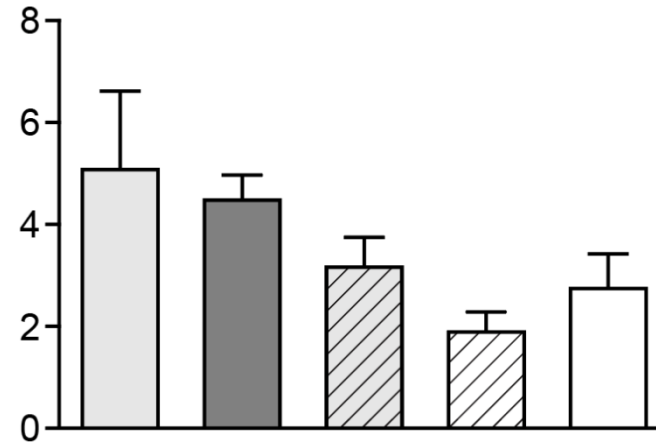
Vector



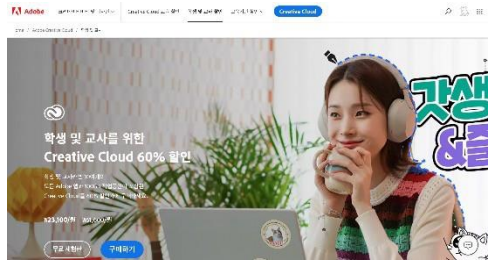Raster Images (Bitmap)




Vector



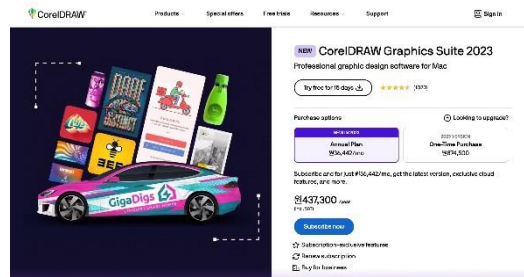
유료프로그램



7일 무료 평가판 (신용
카드 등록후 가능) 첫
해 ₩23,100/
월, 이후 갱신 시 ₩35,200/월



CorelDRAW[®]
GRAPHICS SUITE



15일 무료 평가판 (신
용카드 등록 없음) 월
36,442원






AFFINITY Designer2

30일 무료 평가판
소장용 99,000원





Print
Screen
SysRq





A4



CorelDRAW
GRAPHICS SUITE



AFFINITY
Designer2



INKSCAPE




GIMP





Fig1

Fig1 7.5 inch 기준



슬라이드1 속성	
일반 보안 자세히 이전 버전	
사진 크기	720 x 567
너비	720픽셀
높이	567픽셀
수평 해상도	96 DPI
수직 해상도	96 DPI
비트 수준	24
압축	LZW

Fig1(크기: 7.5 inch,
용량: 29.4KB)

Figure 주출방법-01 속성	
일반 보안 자세히 이전 버전	
사진 크기	2251 x 1636
너비	2251픽셀
높이	1636픽셀
수평 해상도	300 DPI
수직 해상도	300 DPI
비트 수준	24
압축	압축되지 않음

Fig1(크기: 7.5 inch,
용량: 10.8MB)

Figure 주출방법_LZW-01 속성	
일반 보안 자세히 이전 버전	
사진 크기	2251 x 1636
너비	2251픽셀
높이	1636픽셀
수평 해상도	300 DPI
수직 해상도	300 DPI
비트 수준	24
압축	LZW

Fig1(크기: 7.5 inch,
용량: 382KB)



Raster Images

Vector Images



LZW(압축파일)

Fig1(크기: 7.5 inch,
용량: 10.8MB)

Fig1(크기: 7.5 inch,
용량: 382KB)

Fig1(크기: 7.5 inch,
용량: 1.44MB)

Fig1(크기: 7.5 inch,
용량: 72.8KB)

Fig2(크기: 5 inch,
용량: 7.30MB)

Fig2(크기: 5 inch,
용량: 292KB)

Fig2(크기: 5 inch,
용량: 1.31MB)

Fig2(크기: 5 inch,
용량: 73.0KB)

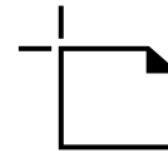

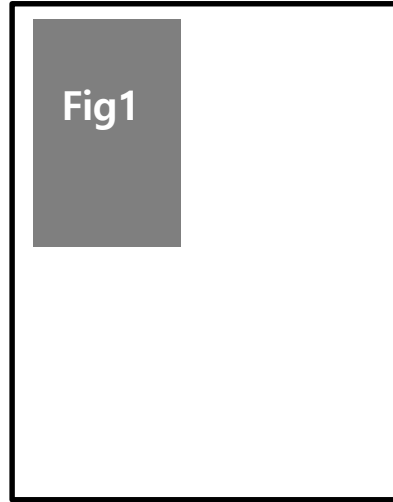

Fig3 (크기: 5.5 inch,
용량: 10.2MB)

Fig3 (크기: 5.5 inch,
용량: 391KB)

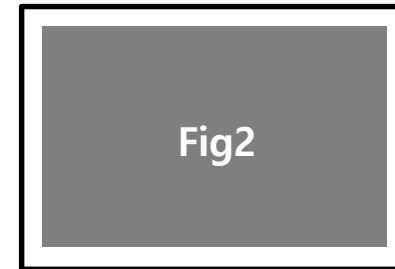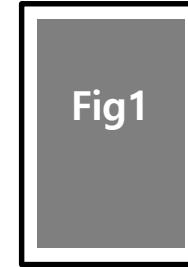
Fig3 (크기: 5.5 inch,
용량: 0.98MB)

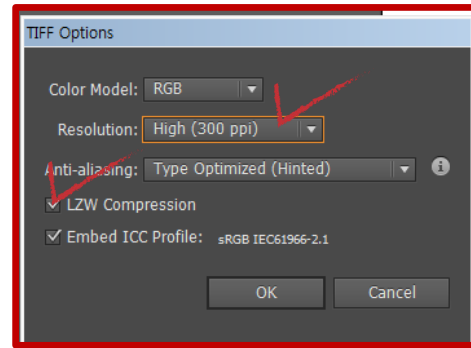
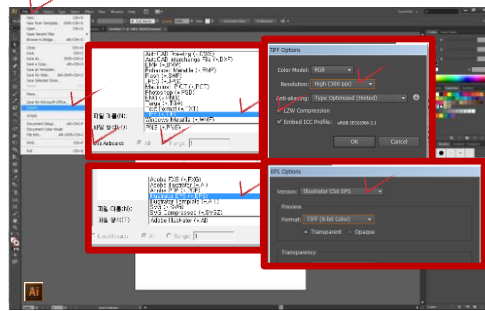
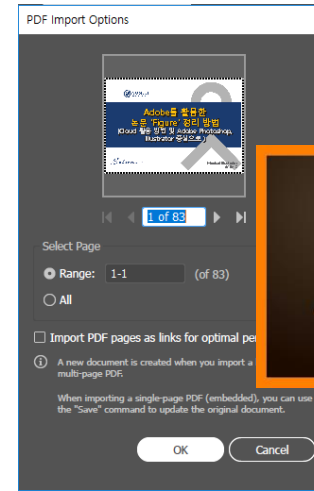


Fig3 (크기: 5.5 inch,
용량: 73.0KB)

A4

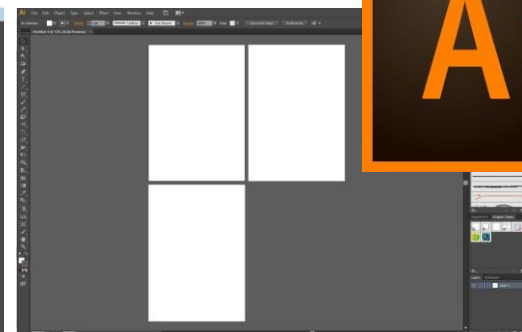
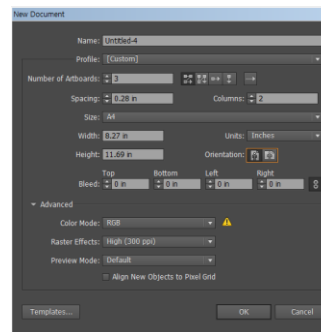

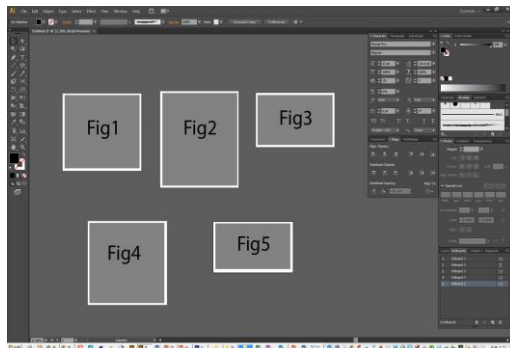


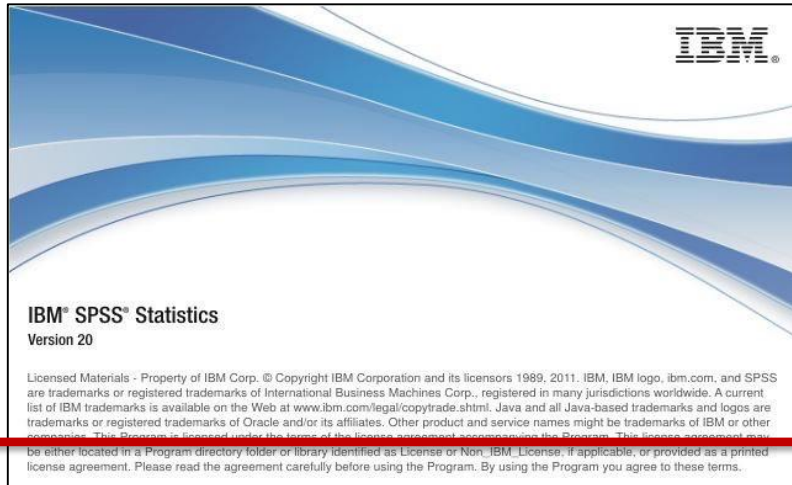
Artboard tool





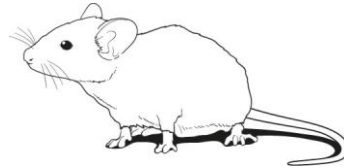
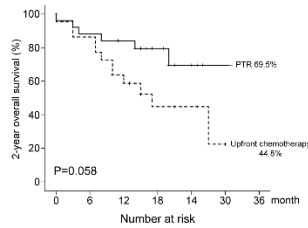
Tiff & eps





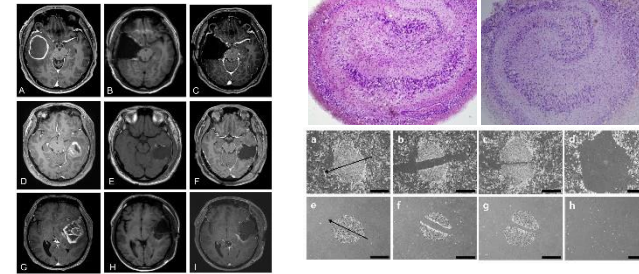
Format: **eps**, **svg**, emf, wmf

Figure types 구분



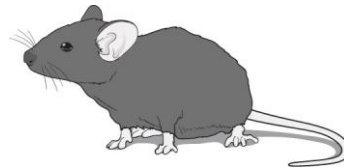
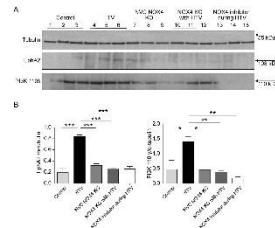
Line Art

(1000dpi 음영 없는 흑백 그래픽)



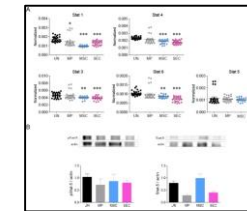
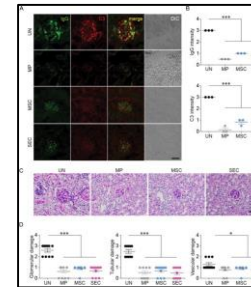
Halftones

(300dpi 흑백 또는 칼라 글씨 없는 이미지)



Grayscale

(300 dpi)



Combination Figures

(600-900dpi 흑백 또는 칼라 글씨 있는 이미지)

Format

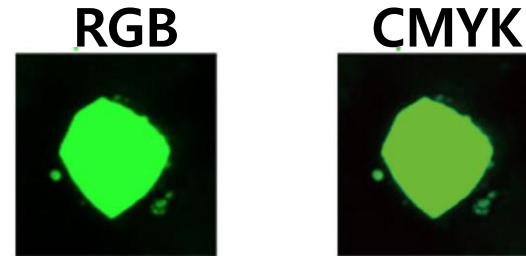
Tiff : Tagged Image File Format
EPS: Encapsulated PostScript

Tiff(Minimum Resolution: 300 dpi)
EPS or PDF



Effectively Creating an abstract figure

- Differentiating RGB and CMYK



- Statistics(SPSS, R, PRISM, Excel, etc), export(eps, svg)
- Resizing resolution and Artboards based on the journal instructions
- Converting into Tiff, eps, or PDF

Raster Images (Bitmap)

PSD

TIFF

JPEG

GIF

PNG

...

Vector

AI

EPS

SVG

EMF

WMF

...

꼭 필요한 Illustrator 메뉴 확인

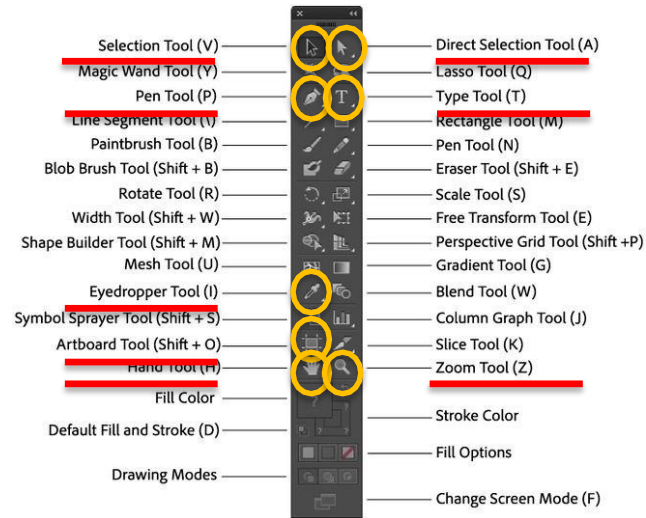
Munu
Control panel

Document

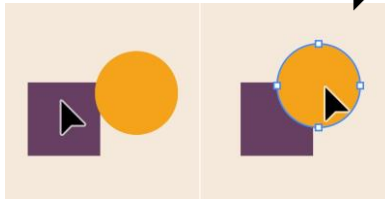
<u>Selection Tool (V)</u>	<u>Direct Selection Tool (A)</u>
<u>Magic Wand Tool (Y)</u>	<u>Lasso Tool (Q)</u>
<u>Pen Tool (P)</u>	<u>Type Tool (T)</u>
<u>Line Segment Tool (L)</u>	<u>Rectangle Tool (M)</u>
Paintbrush Tool (B)	Pen Tool (N)
Blob Brush Tool (Shift + B)	Eraser Tool (Shift + E)
Rotate Tool (R)	Scale Tool (S)
Width Tool (Shift + W)	Free Transform Tool (E)
Shape Builder Tool (Shift + M)	Perspective Grid Tool (Shift + P)
Mesh Tool (U)	Gradient Tool (G)
<u>Eyedropper Tool (I)</u>	Blend Tool (W)
Symbol Sprayer Tool (Shift + S)	Column Graph Tool (J)
Artboard Tool (Shift + O)	Slice Tool (K)
<u>Hand Tool (H)</u>	<u>Zoom Tool (Z)</u>
Fill Color	Stroke Color
Default Fill and Stroke (D)	Fill Options
Drawing Modes	Change Screen Mode (F)

Tools panel

Window panel



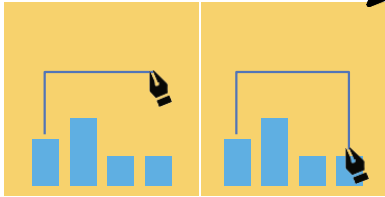
Selection Tool(V)



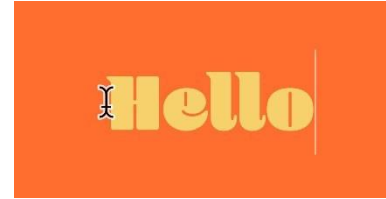Direct selection tool



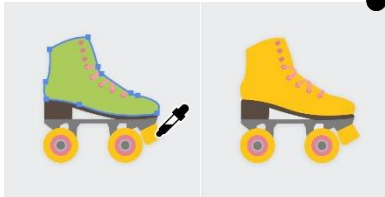Direct selection tool



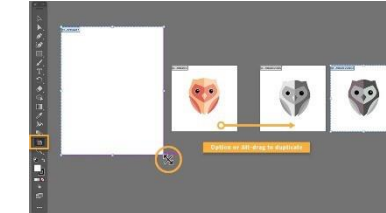
Type Tool



Eyedropper(spoiler)



Artboard Tool



Hand Tool



Zoom Tool



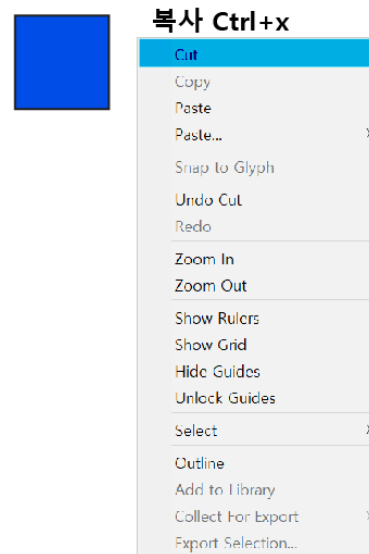
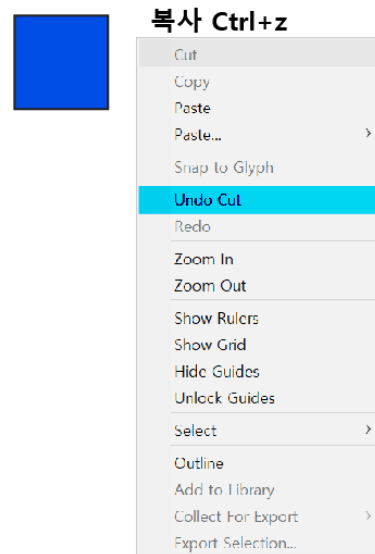
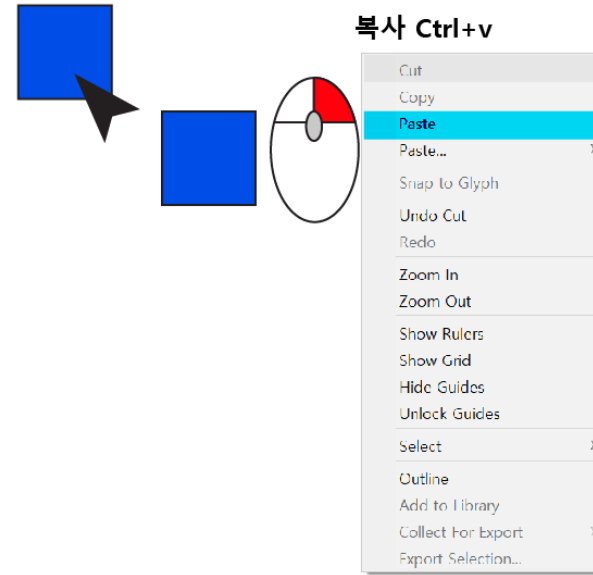
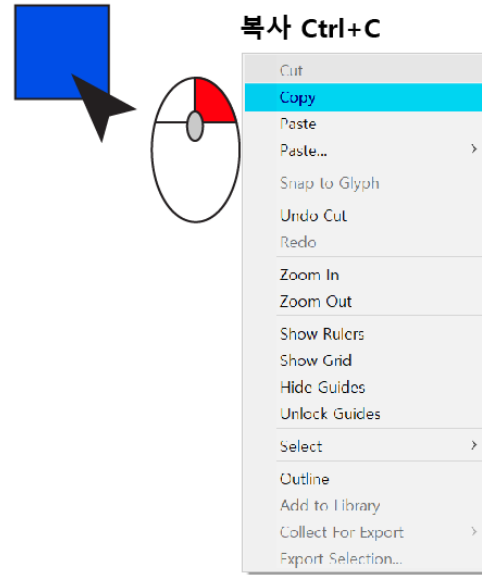
Window 단축키

control + c 복사
control + v 붙여넣기
control + z 실행 취소
control + x 잘라내기
control + f 앞으로 가져오기
control + b 뒤로 보내기
control + 2 고정하기
control + alt + 2 고정해제
control + 3 감추기
control + alt + 3 나타내기
control + G 그룹하기
control + shift + G 그룹풀기

Mac 단축키

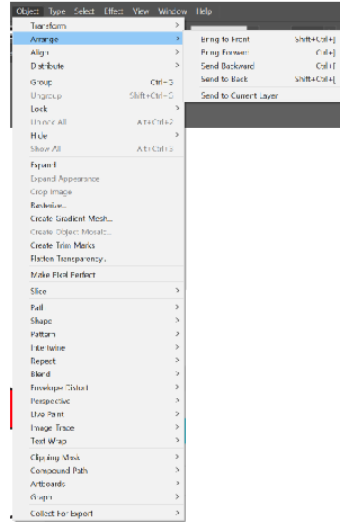
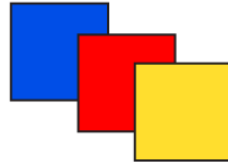
command + c 복사
command + v 붙여넣기
command + z 실행 취소
command + x 잘라내기
command + f 앞으로 가져오기
command + b 뒤로 보내기
command + 2 고정하기
command + alt + 2 고정해제
command + 3 감추기
command + alt + 3 나타내기
command + G 그룹하기
command + shift + G 그룹풀기

Copy & Paste




Arrange

Ctrl+shift+]
Ctrl+shift+[



Bring to Front	Shift+Ctrl+]
Bring Forward	Ctrl+]
Send Backward	Ctrl+[
Send to Back	Shift+Ctrl+[
Send to Current Layer	



Bring to Front	Shift+Ctrl+]
Bring Forward	Ctrl+]
Send Backward	Ctrl+[
Send to Back	Shift+Ctrl+[
Send to Current Layer	




Ctrl+shift+]

Bring to Front	Shift+Ctrl+]
Bring Forward	Ctrl+]
Send Backward	Ctrl+[
Send to Back	Shift+Ctrl+[
Send to Current Layer	



Ctrl+shift+[



Ctrl+]


Bring to Front	Shift+Ctrl+]
Bring Forward	Ctrl+]
Send Backward	Ctrl+[
Send to Back	Shift+Ctrl+[
Send to Current Layer	



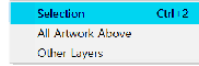Ctrl+[

Bring to Front	Shift+Ctrl+]
Bring Forward	Ctrl+]
Send Backward	Ctrl+[
Send to Back	Shift+Ctrl+[
Send to Current Layer	

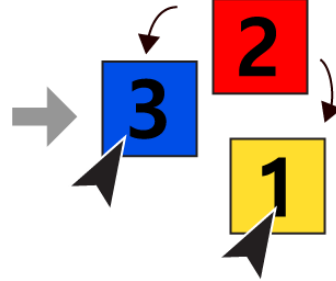
Lock



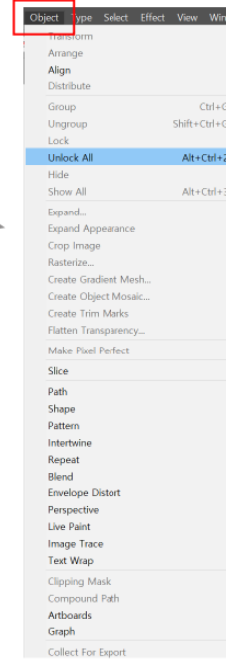
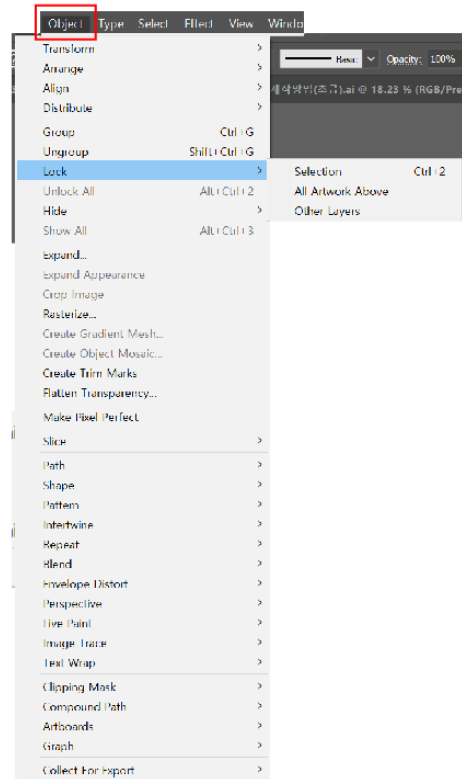
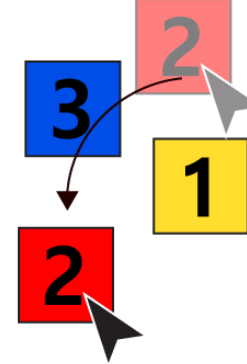
Ctrl+2



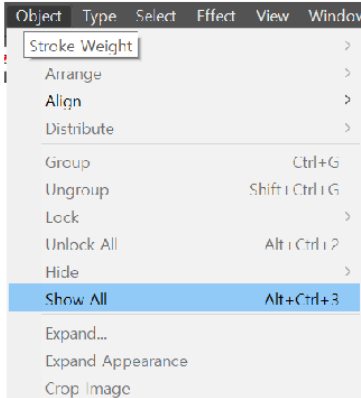
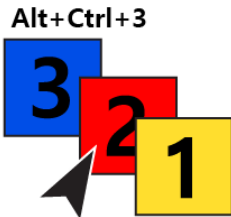
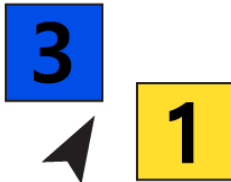
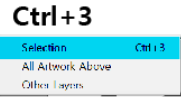
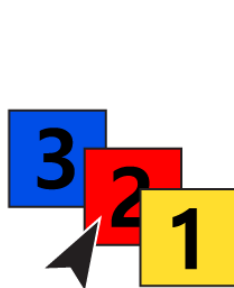

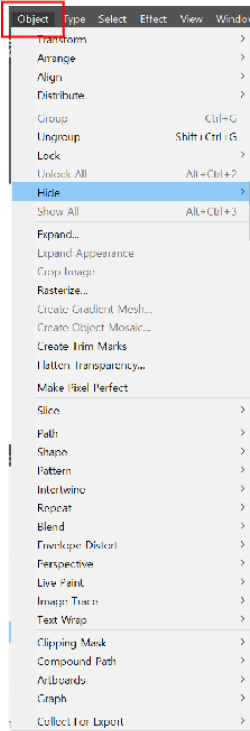
Locked



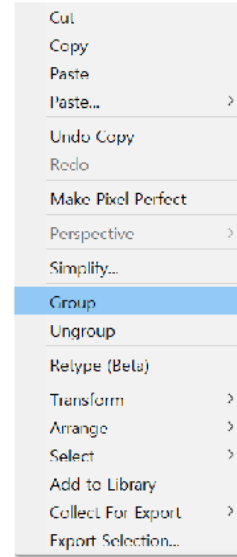
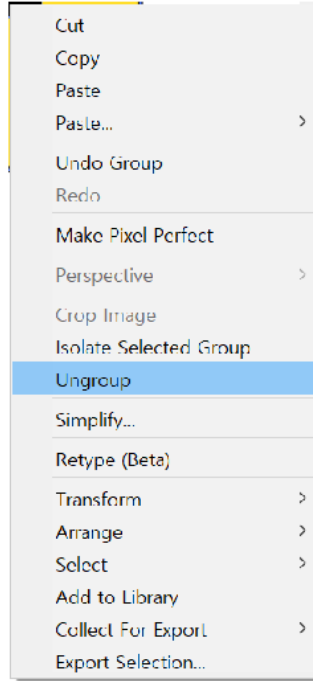

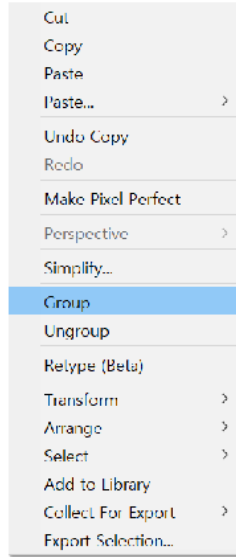

Unlock All
Alt+Ctrl+2


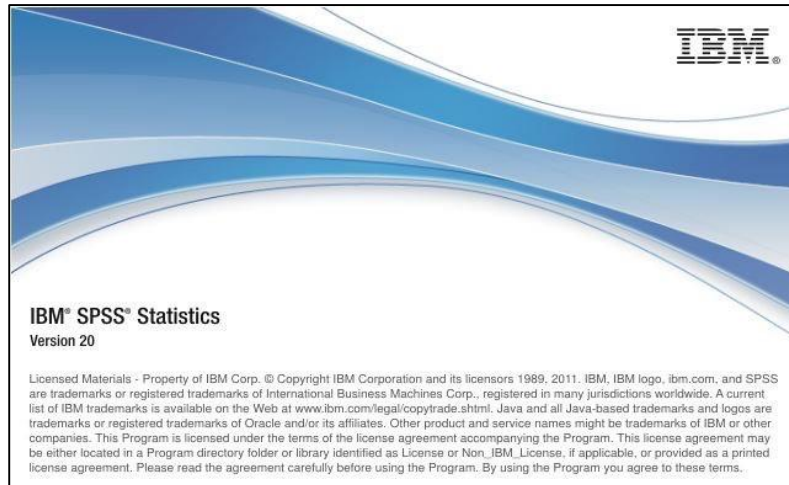


Hide & Show All

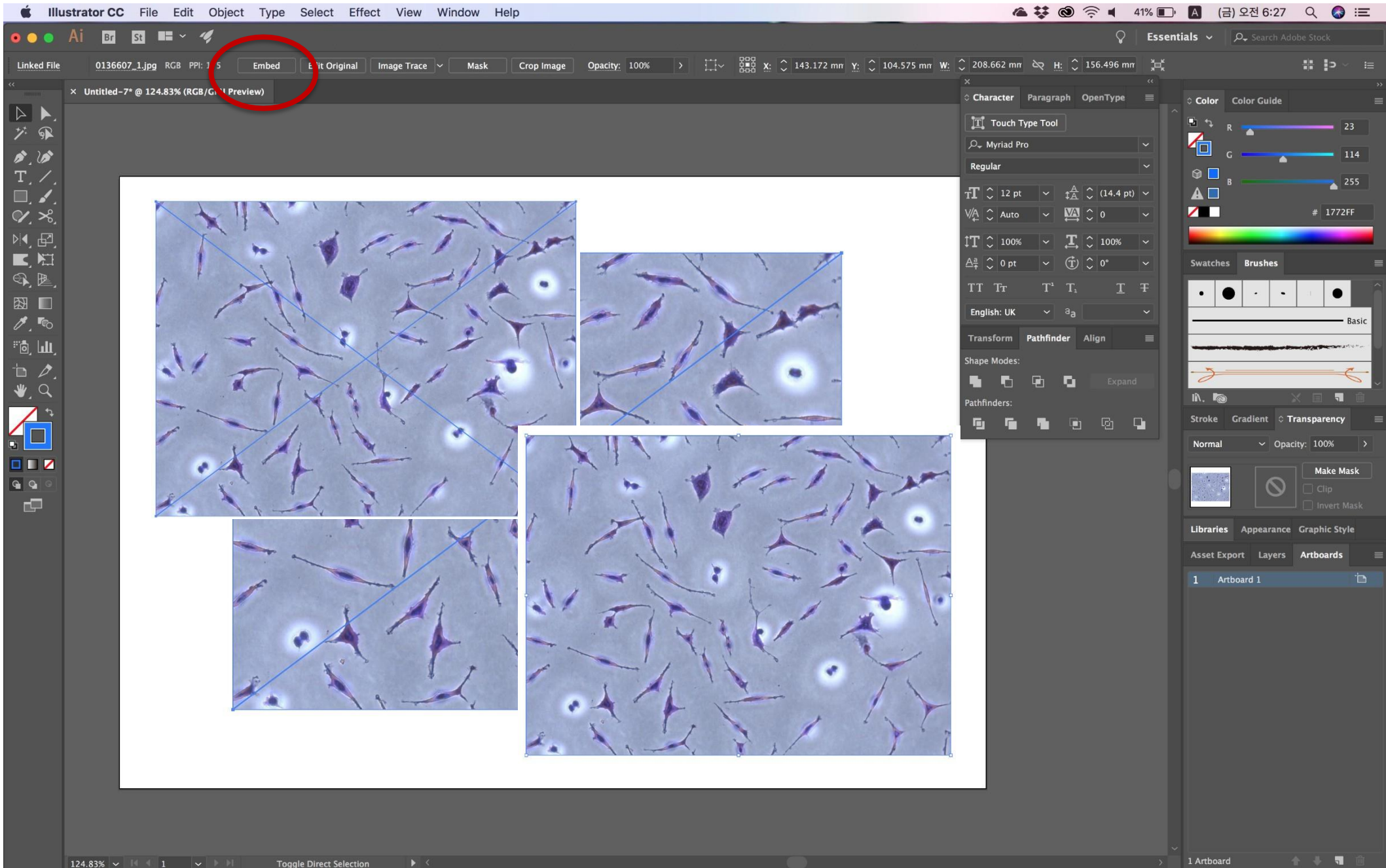


Group, Ungroup

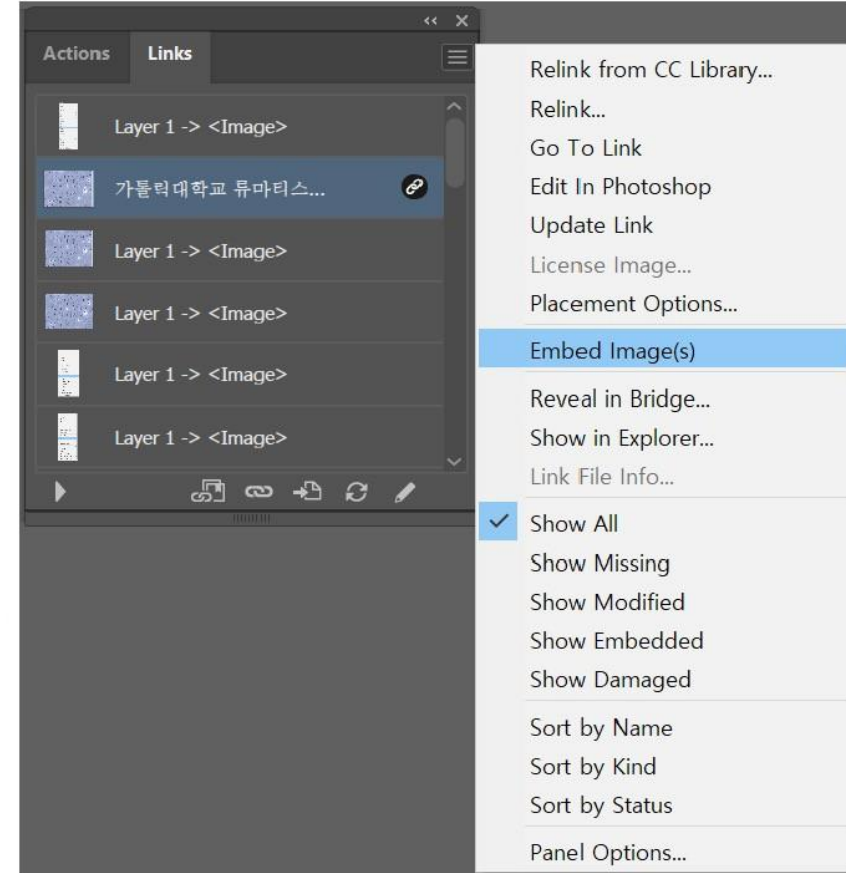
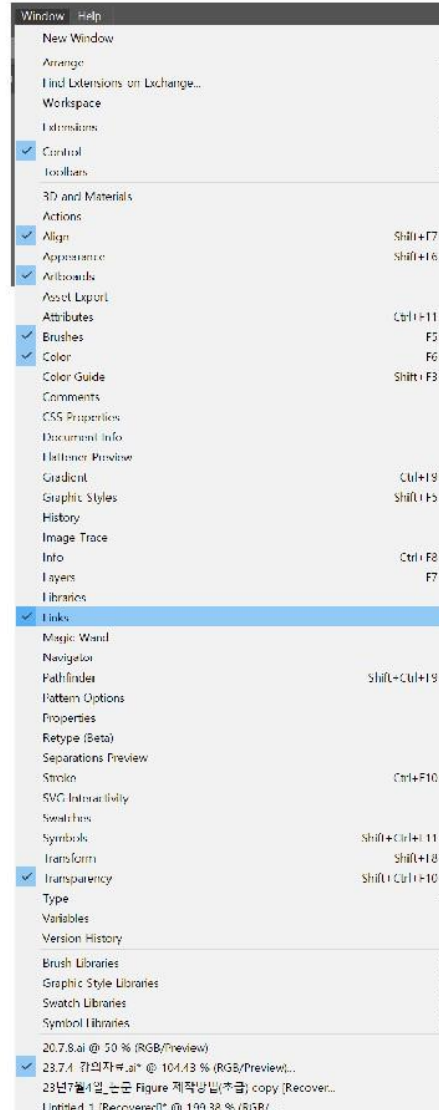
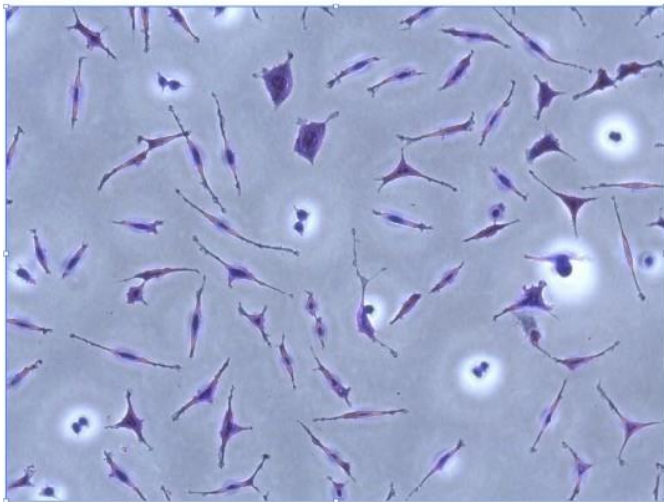
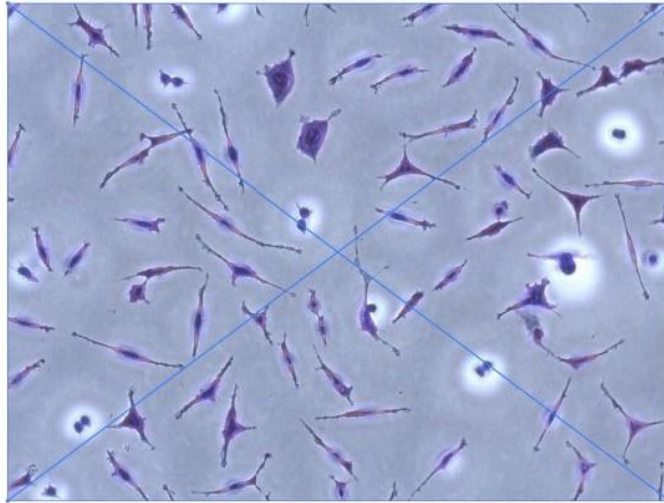




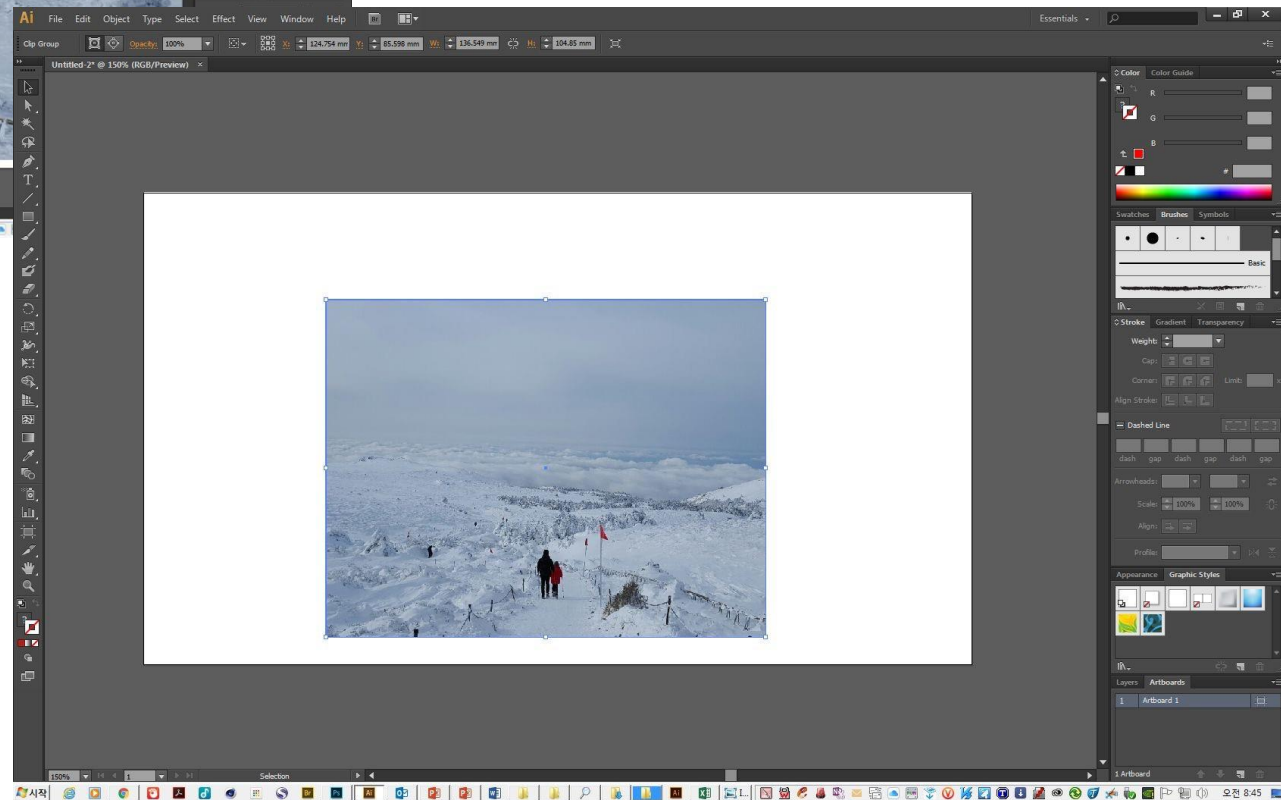
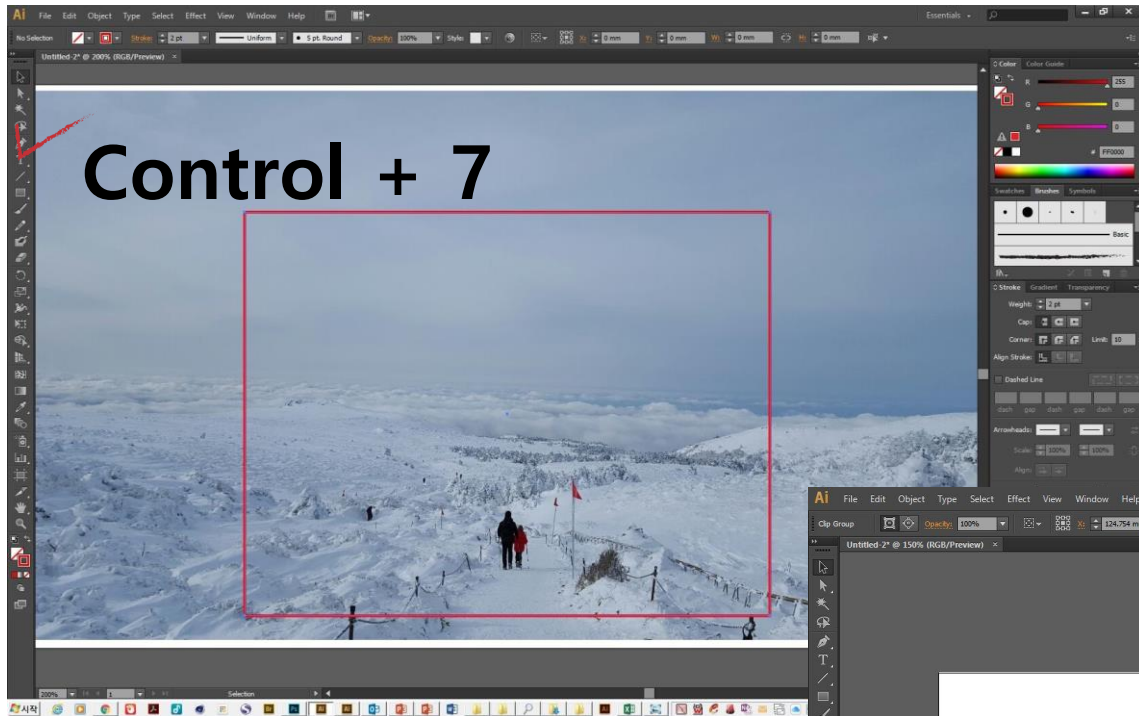
Format: **eps, svg, emf, wmf**

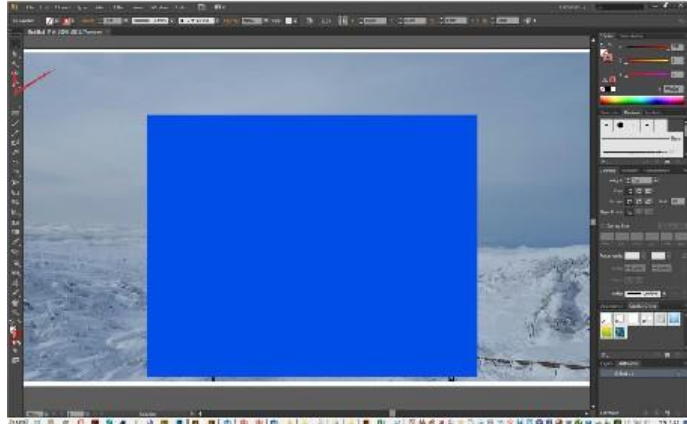


Embed

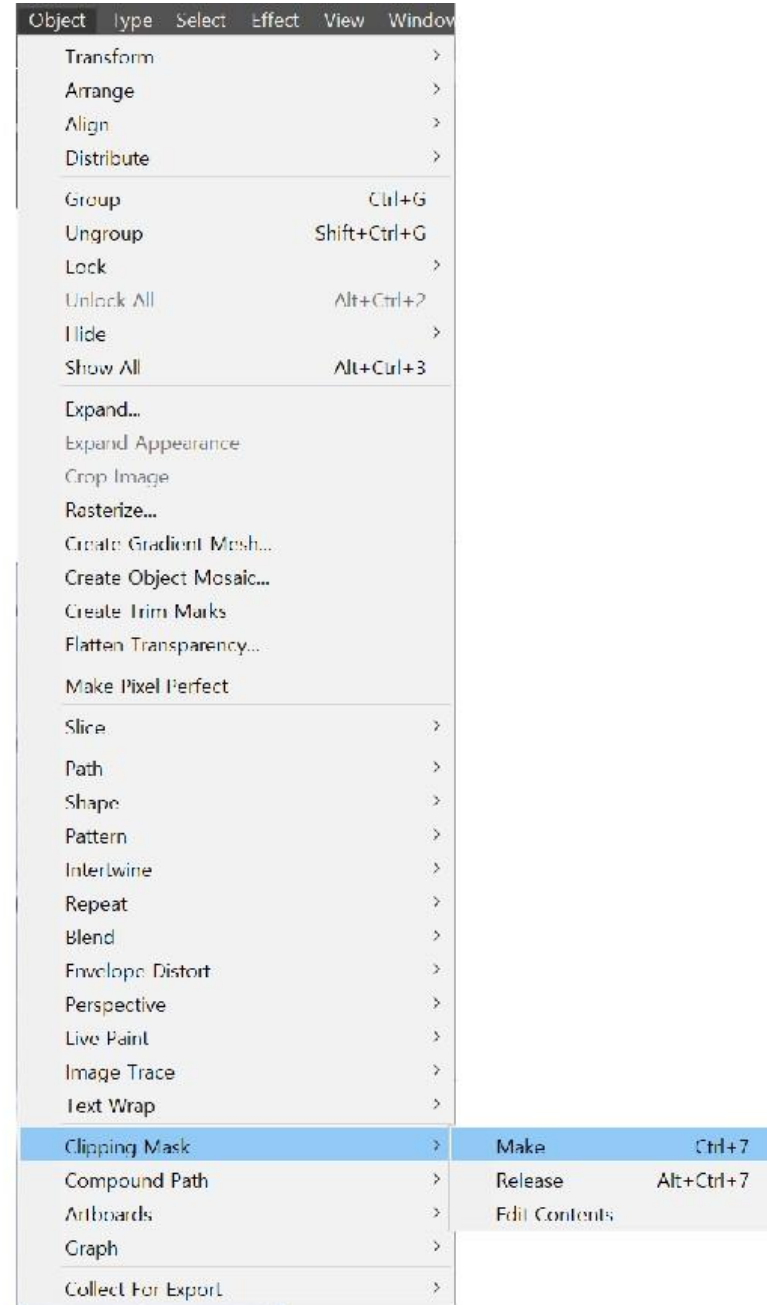


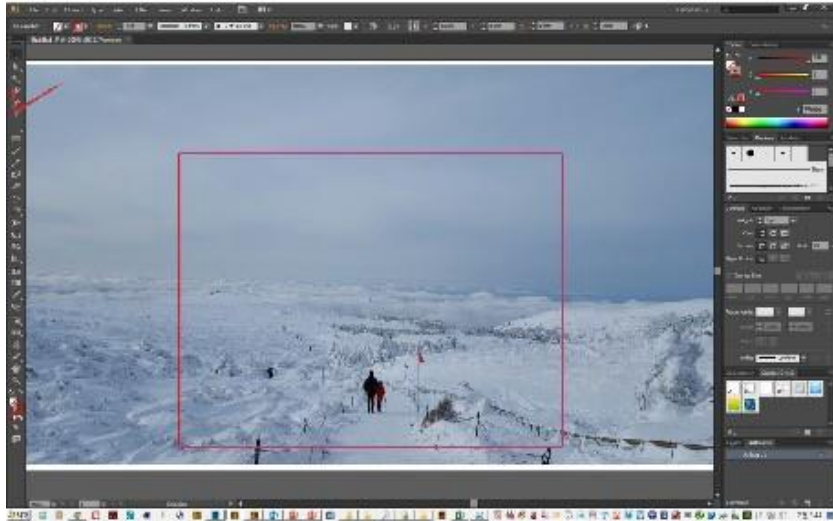
Clipping Mask 기능 및 Align





Control + 7



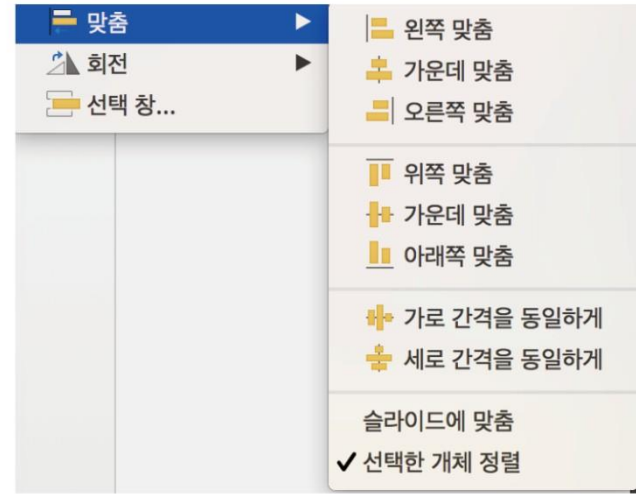
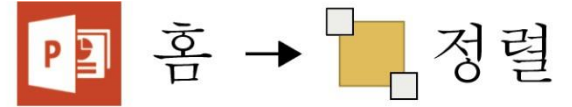
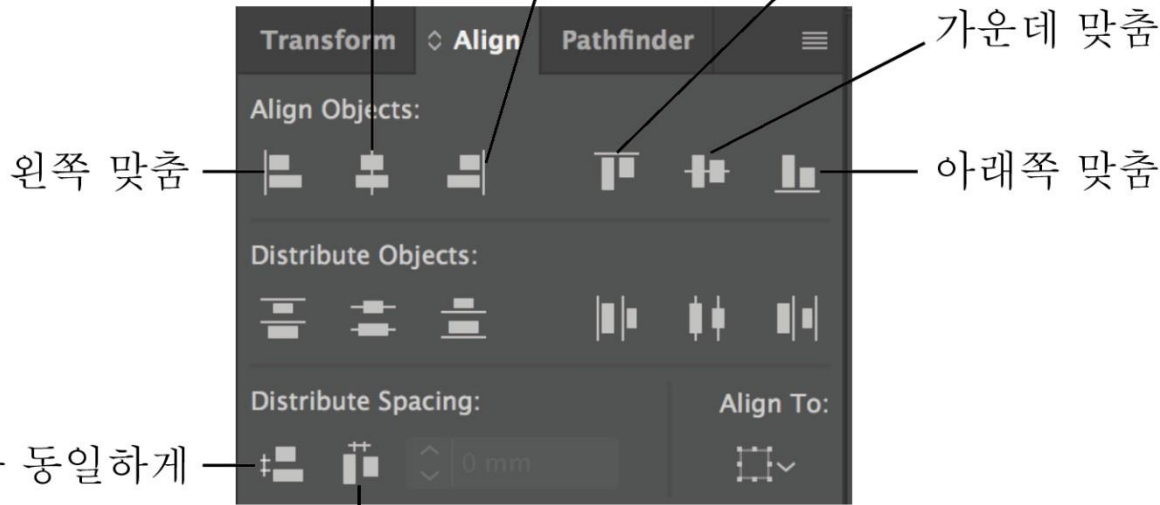


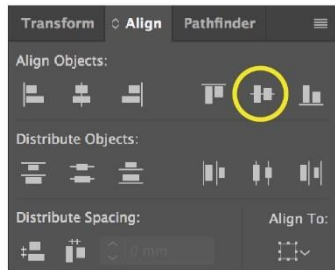

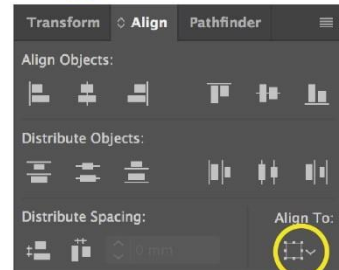
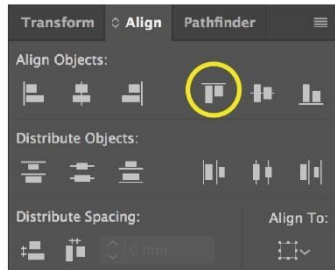

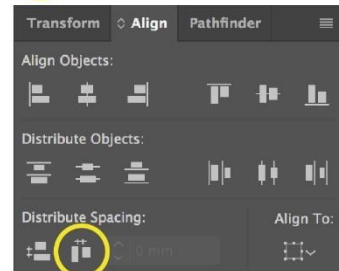

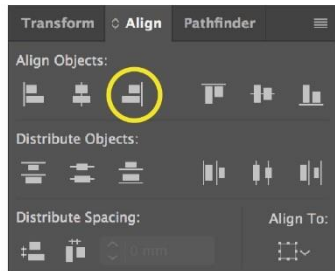
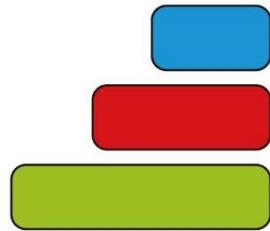
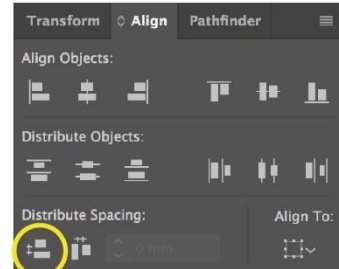
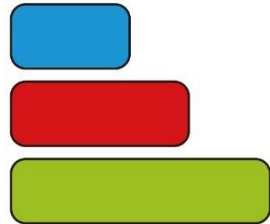
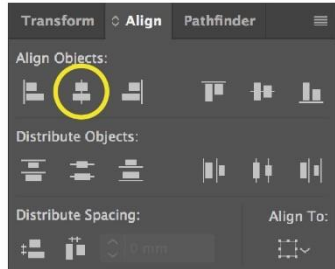
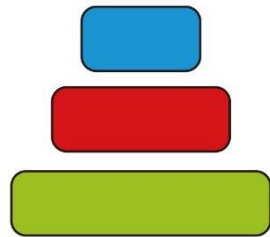
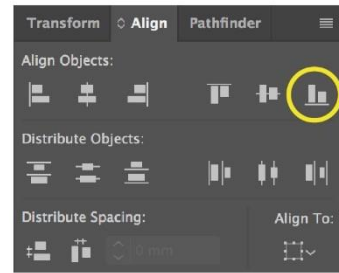
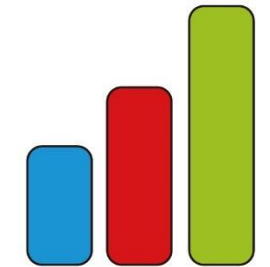
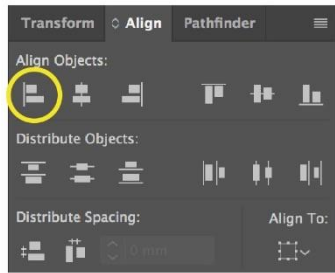
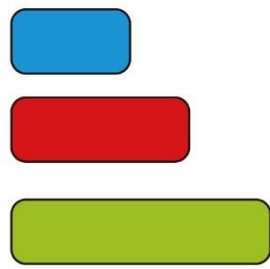
Control + Alt 7

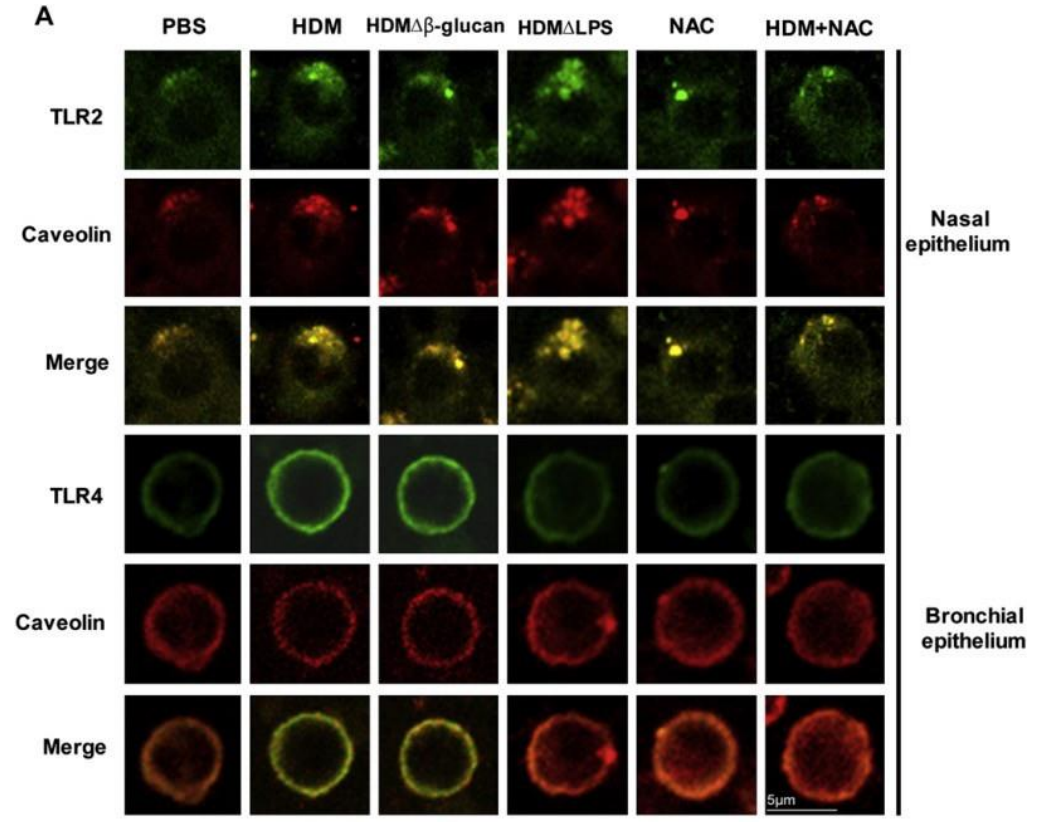
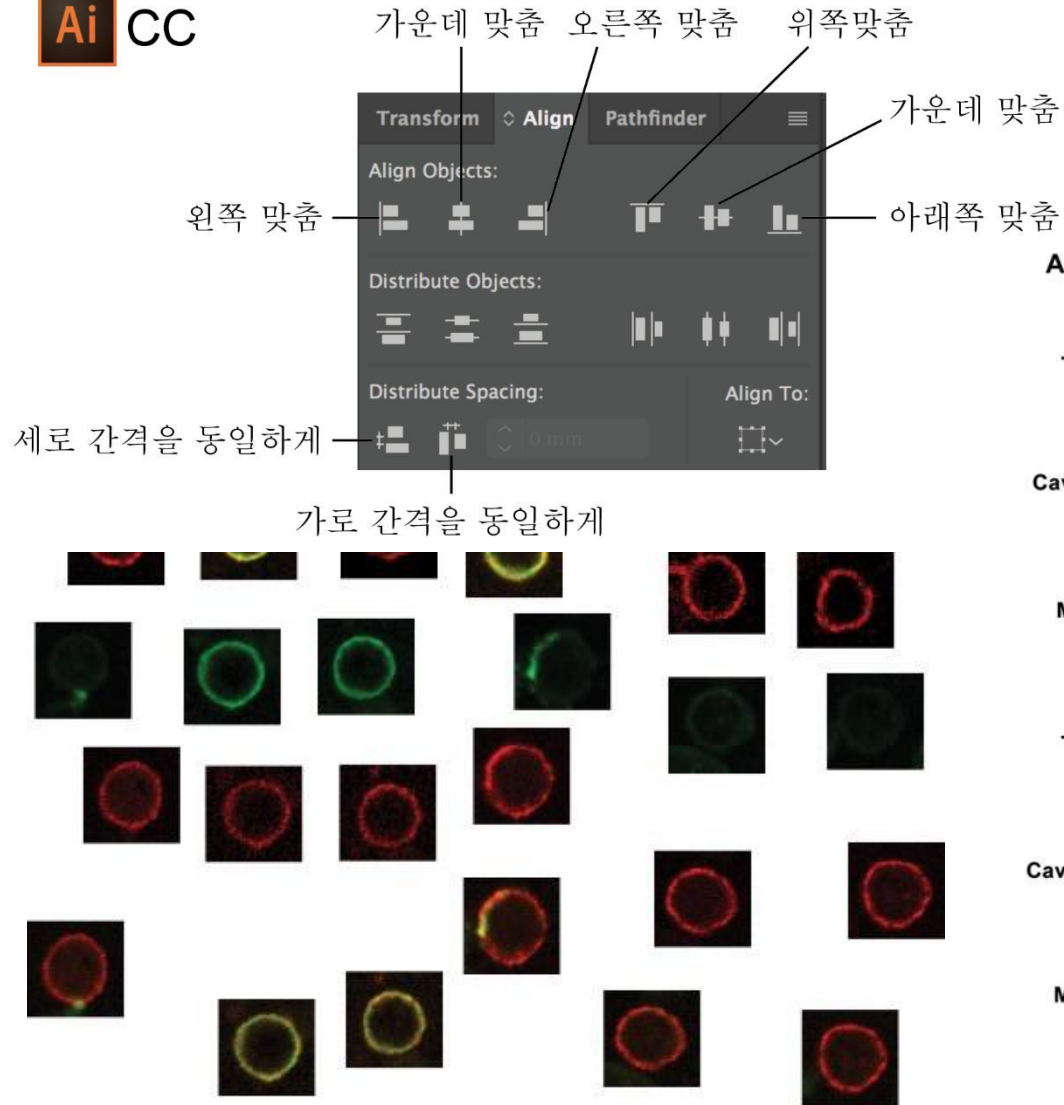
Clipping Mask	>	Make	Ctrl+7
Compound Path	>	Release	Alt+Ctrl+7
Artboards	>	Edit Contents	
Graph	>		
Collect For Export	>		



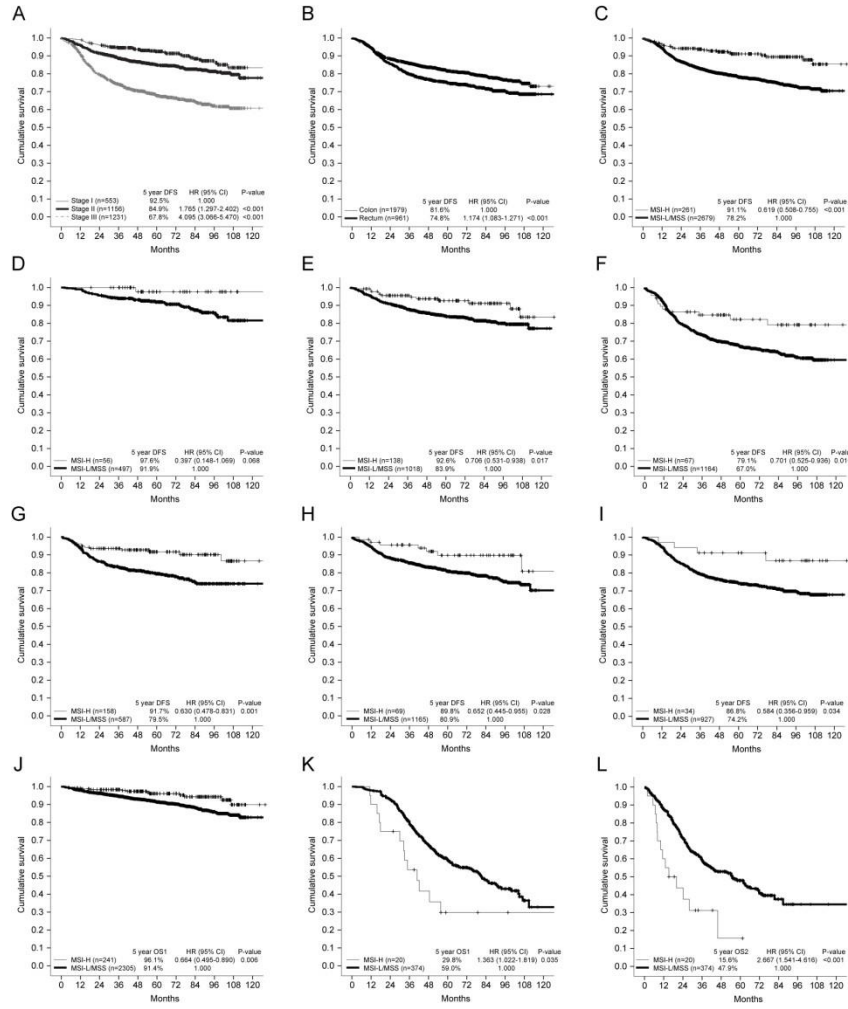
가운데 맞춤 오른쪽 맞춤 위쪽 맞춤



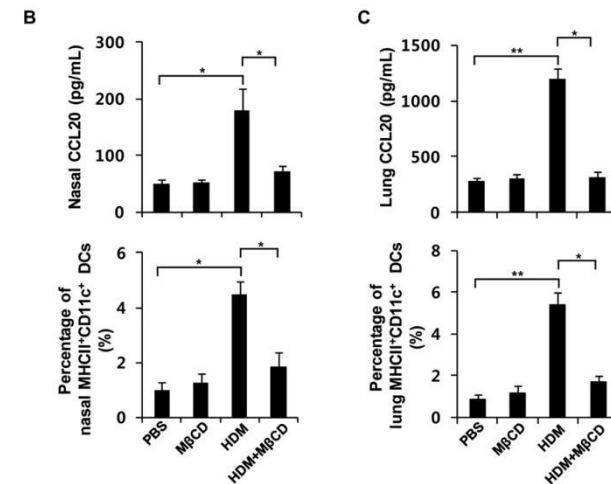
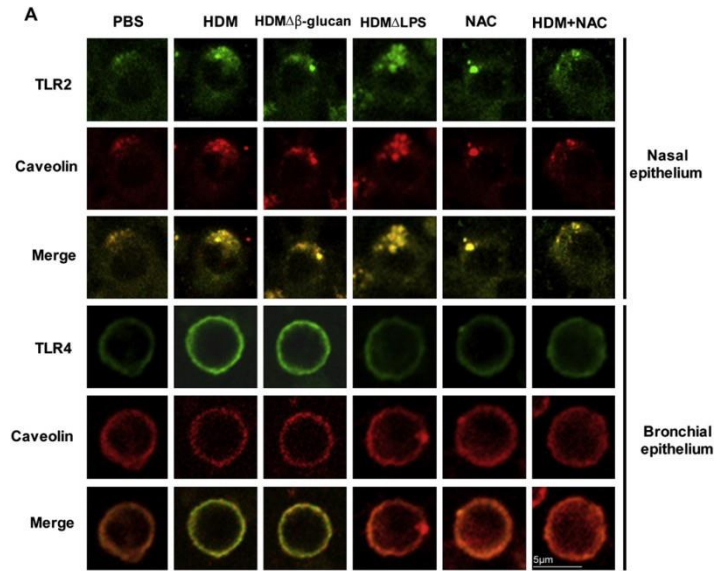


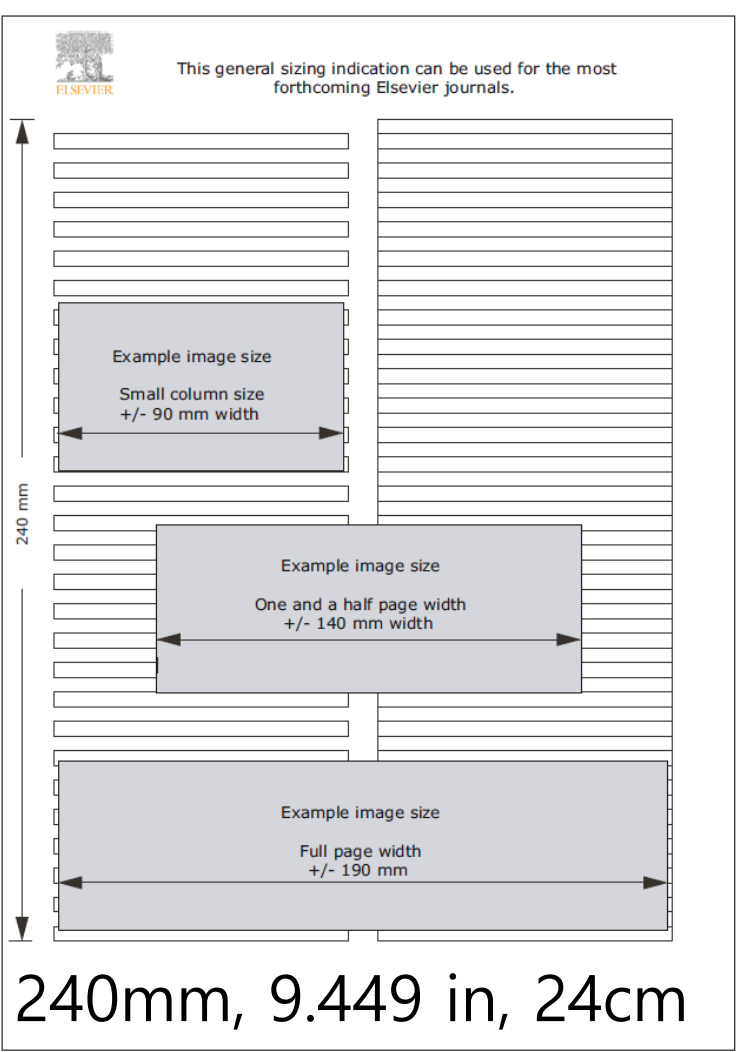
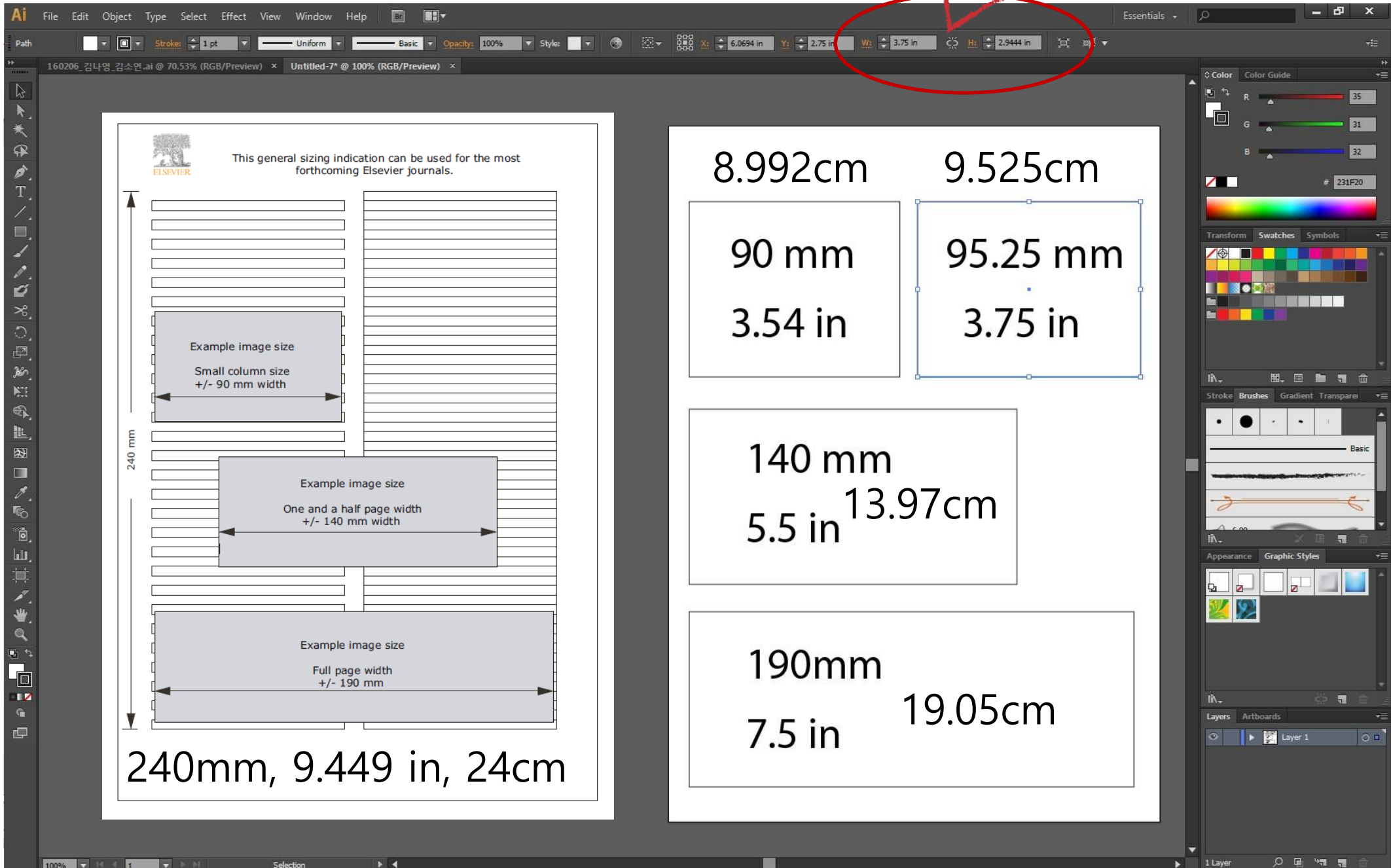


A Type




B Type

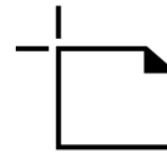


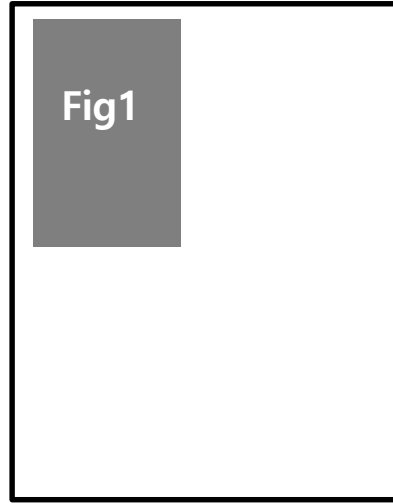


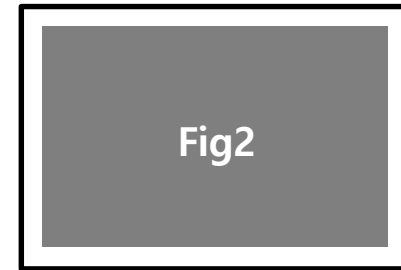

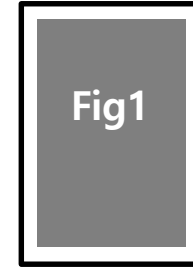
- 8.992cm 9.525cm
- 90 mm 95.25 mm
- 3.54 in 3.75 in
- 140 mm 13.97cm
- 5.5 in
- 190mm 19.05cm
- 7.5 in




A4



Artboard tool



eps



PDF



You can do much more if you save as a cloud document ⓘ

	On your computer	Creative Cloud
Offline access	✓	✓
Cloud syncing to all your devices	✗	✓
Autosaving every change	✗	✓
Version history	✗	✓
Invite to edit	✗	✓

Don't show again




PDF



PPT



PSD



Tiff



PPT 정리



Eps, wmf,
emf, 기타 파일 보관



Tiff & PDF

Check out some of our free online tools

Merge PDF	Compress PDF	PDF Editor	Convert PDF	Split PDF
E-Sign	PDF to Word	PDF to Excel	PDF to PPT	Resize PDF
PDF to JPG	Rotate PDF	PPT to PDF	Excel to PDF	Word to PDF

PDF에서 PPT로

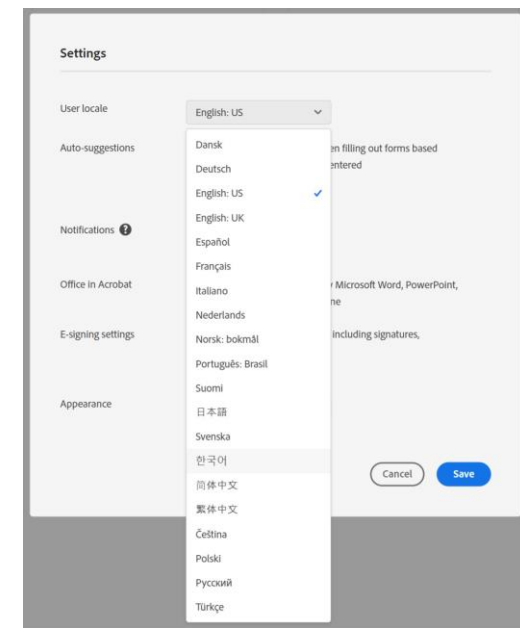
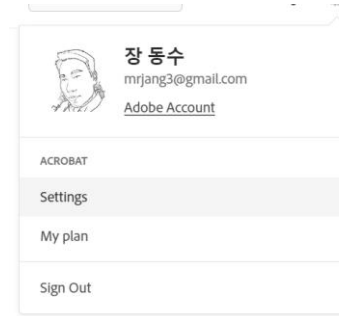
Soda PDF를 사용하여 PDF를 PowerPoint로 빠르게 변환할 수 있습니다. 이 기능은 데스크톱과 온라인 모두에서 사용할 수 있습니다.

PDF를 PPT로 변환하는 방법

- <https://www.sodapdf.com/pdf-to-ppt/>



Adobe Acrobat



Convert

PDF to Word
Convert PDFs to Microsoft Word files

Drag and drop, or [select a file](#)

PDF to PPT
Convert PDFs to Microsoft PowerPoint files

Drag and drop, or [select a file](#)

PDF to Excel
Convert PDFs to Microsoft Excel files

Drag and drop, or [select a file](#)

PDF to JPG
Convert PDFs to JPG or other image formats

Drag and drop, or [select a file](#)

Export a PDF
Convert PDFs to Microsoft Office files, images, and more

Drag and drop, or [select a file](#)

Word to PDF
Convert Microsoft Word files to PDF

Drag and drop, or [select a file](#)

PPT to PDF
Convert Microsoft PowerPoint files to PDF

Drag and drop, or [select a file](#)

Excel to PDF
Convert Microsoft Excel files to PDF

Drag and drop, or [select a file](#)

JPG to PDF
Convert JPG, PNG, and other images to PDF

Drag and drop, or [select a file](#)

Convert to PDF
Turn almost any file into a PDF

Drag and drop, or [select a file](#)

Compress a PDF
Reduce the size of your PDF for easier sharing














Drag and drop, or [select a file](#)

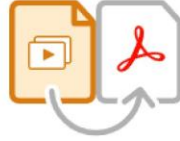Scan & OCR

Turn scans or images into searchable, editable PDFs

[Use on desktop](#)

변환

 PDF를 Word로 PDF를 Microsoft Word 파일로 변환 드래그 앤 드롭 또는 파일 선택	 PDF를 PPT로 PDF를 Microsoft PowerPoint 파일로 변환 드래그 앤 드롭 또는 파일 선택	 PDF를 Excel로 PDF를 Microsoft Excel 파일로 변환 드래그 앤 드롭 또는 파일 선택	 PDF를 JPG로 PDF를 JPG 또는 다른 이미지 형식으로 변환 드래그 앤 드롭 또는 파일 선택
 PDF 내보내기 PDF를 Microsoft Office 파일, 이미지 등으로 변환 드래그 앤 드롭 또는 파일 선택	 Word를 PDF로 Microsoft Word 파일을 PDF로 변환 드래그 앤 드롭 또는 파일 선택	 PPT를 PDF로 Microsoft Powerpoint 파일을 PDF로 변환 드래그 앤 드롭 또는 파일 선택	 Excel을 PDF로 Microsoft Excel 파일을 PDF로 변환 드래그 앤 드롭 또는 파일 선택
 JPG를 PDF로 JPG, PNG 및 다른 이미지를 PDF로 변환 드래그 앤 드롭 또는 파일 선택	 PDF로 변환 거의 모든 파일을 PDF로 변환 드래그 앤 드롭 또는 파일 선택	 PDF 압축 쉽게 공유할 수 있도록 PDF 크기 축소 드래그 앤 드롭 또는 파일 선택	 스캔 및 OCR  스캔 또는 이미지 파일을 검색 및 수정 가능한 PDF로 변환 데스크탑에서 사용




PowerPoint를 PDF로 변환

PDF로 변환할 Microsoft PowerPoint 파일(PPTX 또는 PPT)을 끌어다 놓습니다.

파일 선택





Acute Kidney Injury and Risk of Heart Failure and Atherosclerotic Events

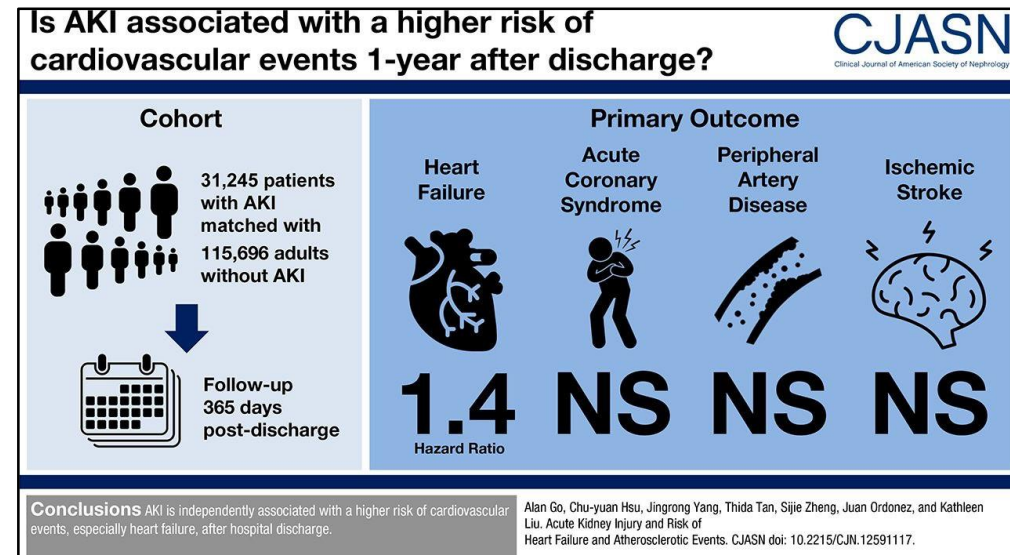
Abstract

Background and objectives: AKI in the hospital is common and is associated with excess mortality. We examined whether AKI is also independently associated with a higher risk of different cardiovascular events in the first year after discharge.

Design, setting, participants, & measurements: We conducted a retrospective analysis of a cohort between 2006 and 2013 with follow-up through 2014, within Kaiser Permanente Northern California. We identified all adults admitted to 21 hospitals who had one or more in-hospital serum creatinine test result and survived to discharge. Occurrence of AKI was on the basis of Kidney Disease: Improving Global Outcomes diagnostic criteria. Potential confounders were identified from comprehensive inpatient and outpatient, laboratory, and pharmacy electronic medical records. During the 365 days after discharge, we ascertained occurrence of heart failure, acute coronary syndromes, peripheral artery disease, and ischemic stroke events from electronic medical records.

Results: Among a matched cohort of 146,941 hospitalized adults, 31,245 experienced AKI. At 365 days postdischarge, AKI was independently associated with higher rates of the composite outcome of hospitalization for heart failure and atherosclerotic events (adjusted hazard ratio [aHR], 1.18; 95% confidence interval [95% CI], 1.13 to 1.25) even after adjustment for demographics, comorbidities, preadmission eGFR and proteinuria, heart failure and sepsis complicating the hospitalization, intensive care unit (ICU) admission, length of stay, and prediagnosed in-hospital mortality. This was driven by an excess risk of subsequent heart failure (aHR, 1.44; 95% CI, 1.33 to 1.66), whereas there was no significant association with follow-up atherosclerotic events (aHR, 1.06; 95% CI, 0.98 to 1.12).

Conclusions: AKI is independently associated with a higher risk of cardiovascular events, especially heart failure, after hospital discharge.



Graphical Abstract (그래픽 초록)이란?

- 논문의 주요 발견 사항을 시각적으로 요약
- 빠르게 이해할 수 있도록 가독성 높은 이미지
- 시작과 끝이 명확
- 순서는 위에서 아래로 또는 왼쪽에서 오른쪽으로


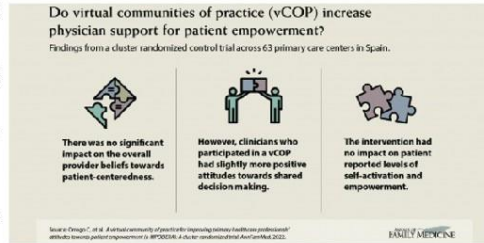
Graphical Abstract (그래픽 초록) 장점

PURPOSE We aimed to evaluate the effectiveness of a virtual community of practice (vCoP) in improving primary health care professionals' (HCPs') attitudes toward empowering patients with chronic disease.

METHODS We conducted a cluster randomized controlled trial. Practices were units of randomization, and primary HCPs and patients were units of analysis. Sixty-three practices in Madrid, Catalonia, and the Canary Islands were randomly allocated to the intervention or control groups. Randomization of practices was performed after HCP and patient recruitment. The patients and statistician were anonymized to group allocation; it was not possible to anonymize HCPs. The intervention was a 12-month multicomponent tailored vCoP built on the Web 2.0 concept and focused on skills toward patient empowerment. The primary outcome was Patient-Provider Orientation Scale (PPOS) score at baseline and at 12 months. The secondary outcome was the Patient Activation Measure (PAM) score.

RESULTS A total of 321 HCPs and 1,921 patients were assessed. The intervention had a positive effect on PPOS total score (0.14 points higher in the vCoP arm; 95% CI, 0.03-0.25; $P = .011$) and the PPOS Sharing subscale (0.3 points higher in the vCoP arm; 95% CI, 0.15-0.44; $P < .001$). No effect was found for the PPOS Caring subscale, and no significant differences were found for PAM scores.

CONCLUSIONS A vCoP led to a minor increase in the PPOS Sharing component and the total score but not in the Caring component. However, considerable uncertainty remains, given the observed attrition and other limitations of the study. Further research is needed on the effectiveness of the vCoP model and on how to improve HCP engagement.



공간을 작게 활용하여 간단
명료하게 메시지 전달

파급성 좋음

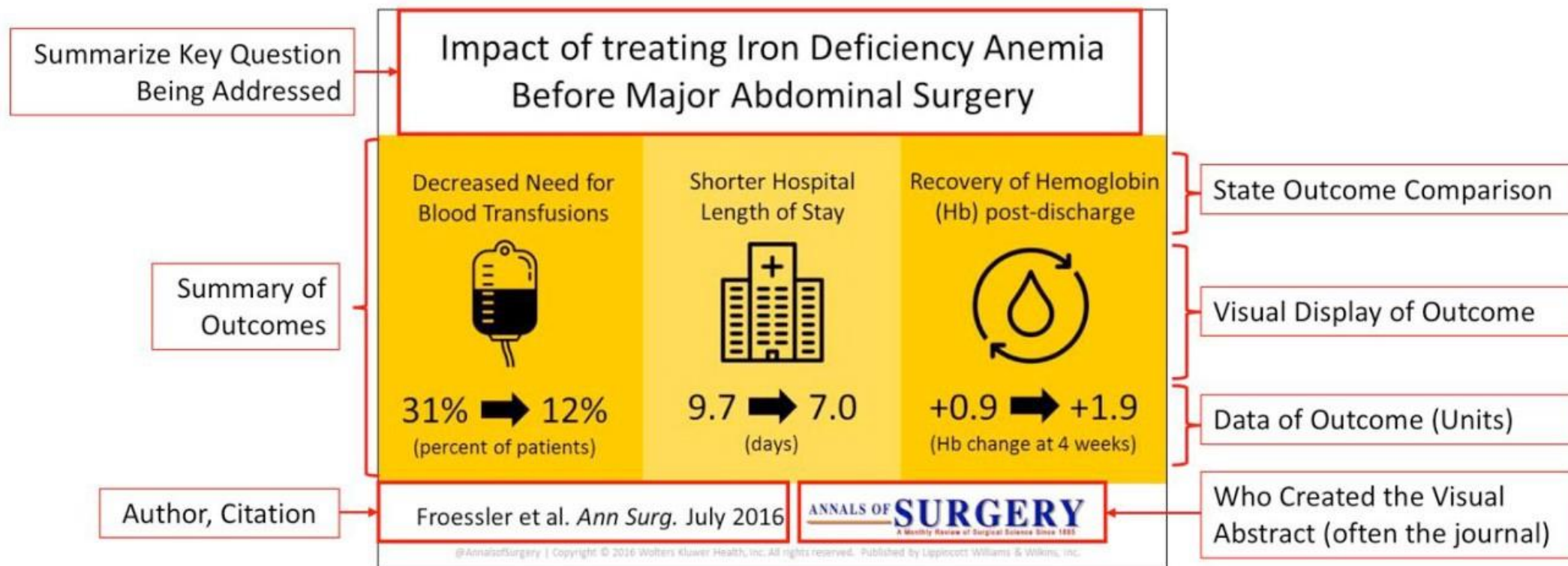
Graphical abstract

제작방법

- Graphical Abstract 유형
- GA 필요한 콘티 설정하는 방법
- Adobe Illustrator Tool 익히기(그림관련 Tool)
- 사진 또는 밑그림을 활용한 그림 그리는 방법
- library 를 활용한 이미지 제작방법
- 통계(SPSS, R, Prism) vector 추출방법
- Target 저널 유형에 맞춰 이미지 추출방법

Graphical Abstract

COMPONENTS OF AN EFFECTIVE VISUAL ABSTRACT



NEJM @NEJM Following

Original Article: Rivaroxaban with or without Aspirin in Stable Cardiovascular Disease (COMPASS) nej.md/2vrQpG6
#VisualAbstract

Rivaroxaban + Aspirin in Stable Cardiovascular Disease

RANDOMIZED, DOUBLE-BLIND, CONTROLLED TRIAL

N=9152	N=9126	N=9117
Rivaroxaban + aspirin	Aspirin alone	Rivaroxaban alone
Primary composite outcome: cardiovascular death, stroke, or MI		
379 patients 4.1%	496 patients 5.4%	448 patients 4.9%
Combination vs. Aspirin: Significant benefit		Rivaroxaban vs. Aspirin: No significant benefit

THE NEW ENGLAND JOURNAL OF MEDICINE Eikelboom et al. 2017

9:05 AM - 5 Oct 2017

JAMASurgery @JAMASurgery Following

While use of #laparoscopy reduced total episode payments, the source of savings is in postacute care ja.ma/2sFcbZJ
#VisualAbstract

Why Methods Matter: Comparing Medicare Payments for Laparoscopic vs. Open Colectomy

Limitation of Standard Risk Adjustment	Solution? Include an Instrumental Variable	Savings of Laparoscopic Colectomy
Inadequately Accounts for Unmeasured Patient Characteristics	Variable Correlated with Surgical Approach Chosen but Not the Outcome	After Standard Risk Adjustment: \$5,547 After Also Accounting for Unmeasured Patient Factors with an Instrumental Variable: \$3,679 (Average Payment Difference Per Patient)

Sheetz et al. JAMA Surg June 2017. JAMA Surgery

3:00 PM - 17 Jun 2017

CJASN @CJASN · 2018년 9월 14일

Certain environmental #pollutants may contribute to poor kidney health bit.ly/2p8yVhb @SirDurhamite @DukeGHI @DukeKidney @dukeresearch

What do we know about perfluoroalkyl and polyfluoroalkyl substances (PFAS)? Can they harm the kidneys?

CJASN Official Journal of American Society of Hypertension

Per- and Polyfluoroalkyl substances (PFAS)	Literature review: PFAS exposure and kidney health	Identified 74 studies
>3000 unique compounds	1990 - 2018	21 Epidemiologic studies 13 Pharmacokinetic studies 40 Toxicological studies
Stain and grease repellent	PubMed	associated with
Military and airport Fire fighting foam	EMBASE	Decreased function
Human exposure via	EBSCO Global Health	
soil	WHO Global Index	
inhalation	Web of Science	
food		
Water		


Conclusions: A growing body of evidence points to PFASs as an environmental threat to kidney health, yet important gaps in our knowledge still exist.

John W. Sessler, Heather Stapleton, Tomihiro Sohma, Ashley Wilmer, Jiali Zhou, and Li Ebony Bawar. *Perfluorinated Chemicals as Emerging Environmental Threats to Kidney Health: A Scoping Review*. CJASN doi:10.2215/CJN.04571818

3 11

Graphical abstract

Reducing surgical site infections in low-income and middle income countries (FALCON): a pragmatic, multicentre, stratified, randomised controlled trial
NIHR Global Research Health Unit on Global Surgery




1 The study	2 Findings												
<p>Participants: 5788 adult and paediatric patients undergoing clean-contaminated or contaminated or dirty abdominal surgery</p> <p>Intervention and comparator: 2x2 factorial trial of skin preparation solutions (2% alcoholic chlorhexidine or 10% aqueous povidone-iodine) and abdominal closing sutures (triclosan-coated or non-coated)</p> <p>Primary outcome: Surgical site infection 30 days after surgery</p> <p>Key limitation: The trial included a heterogeneous mix of operation types, these represented real world surgical case mix</p>	<p>There was no evidence of a difference in the risk of surgical site infection with alcoholic chlorhexidine compared to povidone-iodine, or with triclosan-coated sutures compared to non-coated sutures</p> <p>Fascial closures</p> <table border="1"> <tr> <td>Non-coated</td> <td>Number assigned: 2644</td> <td>Reference</td> </tr> <tr> <td>Triclosan-coated sutures</td> <td>2640</td> <td>0.94*</td> </tr> </table> <p>95%CI 0.85 to 1.04; p=0.217</p> <p>Skin preparations</p> <table border="1"> <tr> <td>Povidone-iodine</td> <td>2635</td> <td>Reference</td> </tr> <tr> <td>Alcoholic chlorhexidine</td> <td>2649</td> <td>0.94*</td> </tr> </table> <p>95%CI 0.85 to 1.04; p=0.216</p>	Non-coated	Number assigned: 2644	Reference	Triclosan-coated sutures	2640	0.94*	Povidone-iodine	2635	Reference	Alcoholic chlorhexidine	2649	0.94*
Non-coated	Number assigned: 2644	Reference											
Triclosan-coated sutures	2640	0.94*											
Povidone-iodine	2635	Reference											
Alcoholic chlorhexidine	2649	0.94*											
3 Research in context													

Before this study	Added value	Implications
WHO recommended alcoholic chlorhexidine and triclosan sutures based on low to moderate quality of evidence.	FALCON is a high quality trial showing no superiority of either alcoholic chlorhexidine nor triclosan sutures for surgical patients in low-income and middle-income countries.	The guidance on alcoholic chlorhexidine and triclosan sutures for low-income and middle-income countries should be reviewed.

THE LANCET The best science for better lives

Slide Title Goes Here
Please use White Text or Gold Text, Centered

Gastric cancer Obese D2



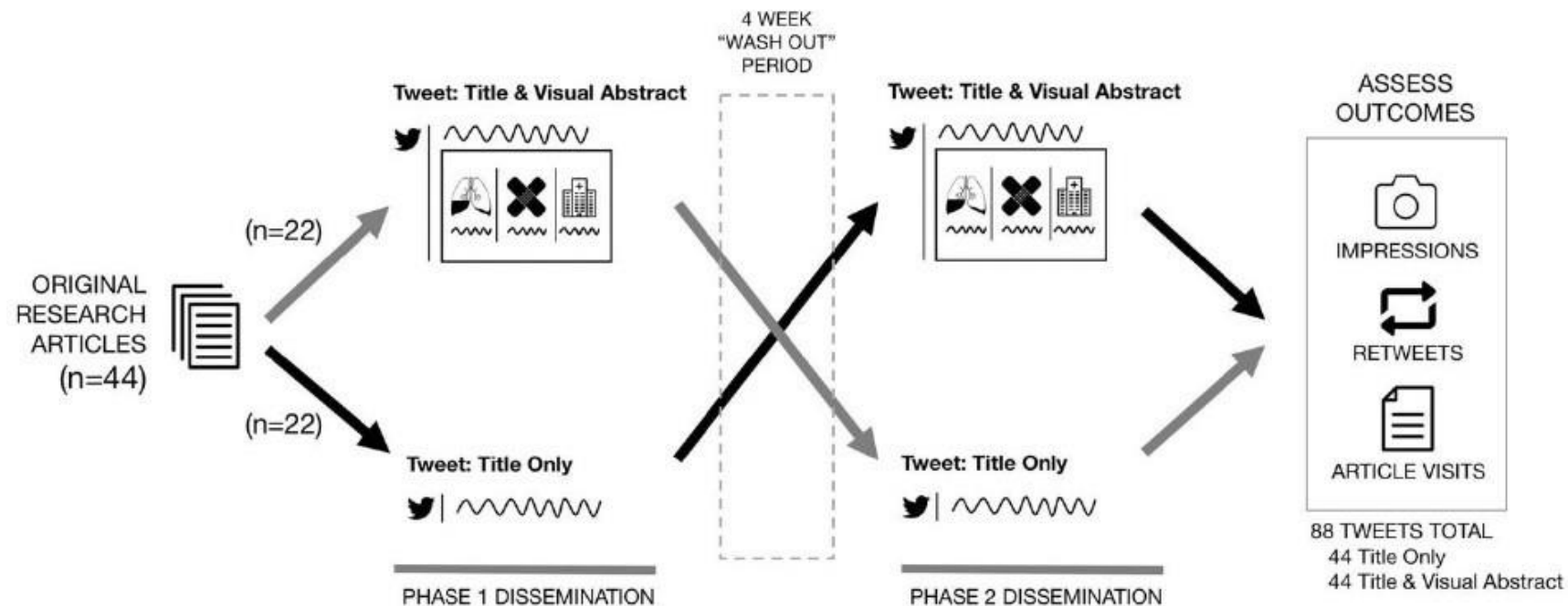
Short-term	Long-term
<p>OP time: Open = Lap = Robot</p> <p>Bleeding: Open > Lap = Robot</p> <p>Lymph nodes: Robot > Open > Lap</p> <p>Complication: Open = Lap = Robot</p>	<p>Complication: Open = Lap = Robot</p> <p>Survival: Robot > Lap > Open</p>

Open Lap Robot

Author et al. Ann Surg Oncol.
Visual Abstract @Member for @AnnSurgOncol

ANNALS OF SURGICAL ONCOLOGY

Figure 1. Study Design. Prospective, Case-Control Crossover Study to Evaluate the Impact of Visual Abstracts on Twitter



Study conducted between July 2016 and December 2016 using articles published the same year. All articles in this study were tweeted from the Annals of Surgery account (Twitter: @AnnalsOfSurgery). Outcomes data were aggregated from Twitter Analytics and compared using matched-pair t-test analysis.

TABLE 1. Case-control Crossover Results: Title Alone Versus Title with Visual Abstract

Outcomes (Mean)	Title Alone (n = 44)	Title with Visual Abstract (n = 44)	Increase of Outcome with Visual Abstract	P*
Impressions	3073.3	23611.2	7.7 fold	<0.001
Retweets	11.0	92.1	8.4 fold	<0.001
Article visits	65.6	175.4	2.7 fold	<0.001

*Comparison of means using matched-pair *t* test analysis comparing 88 total tweets from 44 articles in the case-control crossover study.

Definitions: Impressions (number of times tweet is seen), Retweets (number of times a tweet is shared), article visits (number of times link to article was clicked from tweet).

cell graphical abstract

인기 최신 사용자 사진 동영상

1 22 64

이 스크린 보기

Claire Dessalles @ClaireDessalles · 2021년 3월 23일
My first first-author paper is finally out in @Cell Sci !! 🎉

Super happy and excited to share with you all this review on Pericyte mechanics and mechanobiology!

We discuss all the aspect present in this **graphical abstract** 🌟

[jcs.biologists.org/content/134/6/...](https://jcs.biologists.org/content/134/6/)

9 48 331

이 스크린 보기

Andres F. Cardona @AndresFCardonaZ · 2019년 7월 29일
Lung cancer graphical abstract of the day. Tracing oncogene rearrangements in the mutational history of LUAD. Lee et al. Cell. 2019;177:1842-1857.

Trading Oncogene Rearrangements in the Mutational History of Lung Adenocarcinoma

6 17

이 스크린 보기

Nick Borchering @thelhumanBorch · 1월 7일
About to submit using TCR vectorization in single-cell and just too pumped not to share our **graphical abstract**! @BrestoffLab @voigt_drew

9 16 139

이 스크린 보기

graphical abstract

인기 최신 사용자 사진 동영상

#JMA the better the child's chance of remission and staying off treatment in the longer term. #Lvetitis is a complicating factor, however... Thanks @KearsleyFleet and team! pubmed.ncbi.nlm.nih.gov/36104094/

Conekta @conekta-ciencia · 9월 16일
One more exciting **#graphicalabstract** that we designed for @666brunno999 for an article published in @CurrentBiology showing that colorful **#birds** are the most threatened ones considering **#animaltrade**! Check it out authors.elsevier.com/doi/article/S09...

The TROPICS are the epicentre of COLOUR in passerine assemblages

1 9

Laura Dearden @lauradearden3 · 9월 14일
I've amended the **graphical abstract** for this paper in Current Biology about baby sleep that's doing the rounds today, based on my experience of an n=2. #cantsleepwontsleep #ishouldhavesharesinStarbucks

"5-minute carrying, 5- to 6-minute sitting before bed"

2 2 9

kumi O kuroda @kumi_kuroda · 9월 14일
A method to soothe and promote sleep in crying infants utilizing the transport response [cell.com/current-biology](https://www.cell.com/current-biology)...

이 스크린 보기

PCU foam

PCU foam with FR

Death rate 5.2% (matched statin users)

Statin

Death rate 9.4% (matched statin nonusers)

COVID-19 Waves

Public health researchers, Policy makers

Deep Neural Network

Highly Accurate State-Level Gum Ownership Prevalence

228Ra

Affordable > 500 Wh/kg

> 1,000 cycles

Li₂S shuttle

Insulating 5 Li dendrites

Cracking solid electrolyte

232Th

100% Natural

228Ac

Open Access Review

New Immunometabolic Strategy Based on Cell Type-Specific Metabolic Reprogramming in the Tumor Immune Microenvironment

by Ji-Yong Sung^{1,*} and Jae-Ho Cheong^{2,3,4,*}

¹ Department of Laboratory Medicine, Yonsei University College of Medicine, Seoul 03722, Korea

² Department of Surgery, Yonsei University College of Medicine, Seoul 03722, Korea

³ Yonsei Biomedical Research Institute, Yonsei University College of Medicine, Seoul 03722, Korea

⁴ Department of Biochemistry & Molecular Biology, Yonsei University College of Medicine, Seoul 03722, Korea

* Authors to whom correspondence should be addressed.

Academic Editor: Piotr Dziegiel

Cells **2022**, *11*(5), 768; <https://doi.org/10.3390/cells11050768>

Received: 7 January 2022 / Revised: 17 February 2022 / Accepted: 21 February 2022 / Published: 22 February 2022

(This article belongs to the Special Issue *New Aspects of Targeting Cancer Metabolism in Therapeutic Approach*)

[View Full-Text](#)

[Download PDF](#)

[Browse Figures](#)

[Citation Export](#)

Abstract

Immunometabolism is an emerging discipline in cancer immunotherapy. Tumor tissues are heterogeneous and influenced by metabolic reprogramming of the tumor immune microenvironment (TIME). In the TIME, multiple cell types interact, and the tumor and immune cells compete for limited nutrients, resulting in altered anticancer immunity. Therefore, metabolic reprogramming of individual cell types may influence the outcomes of immunotherapy. Understanding the metabolic competition for access to limited nutrients between tumor cells and immune cells could reveal the breadth and complexity of the TIME and aid in developing novel therapeutic approaches for cancer. In this review, we highlight that, when cells compete for nutrients, the prevailing cell type gains certain advantages over other cell types; for instance, if tumor cells prevail against immune cells for nutrients, the former gains immune resistance. Thus, a strategy is needed to selectively suppress such resistant tumor cells. Although challenging, the concept of cell type-specific metabolic pathway inhibition is a potent new strategy in anticancer immunotherapy. [View Full-Text](#)

Keywords: immunometabolism; tumor microenvironment; metabolic reprogramming; immune checkpoint inhibitor

[Show Figures](#)

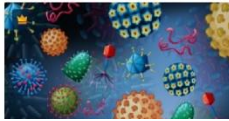
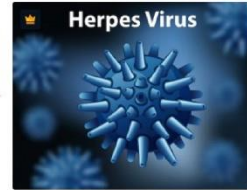
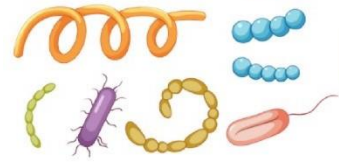
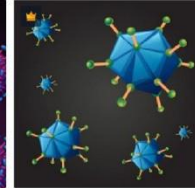
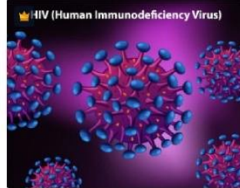
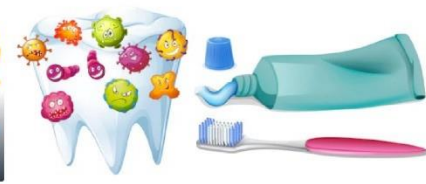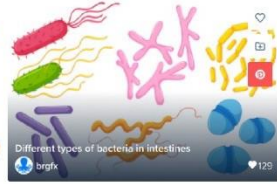


Graphical abstract



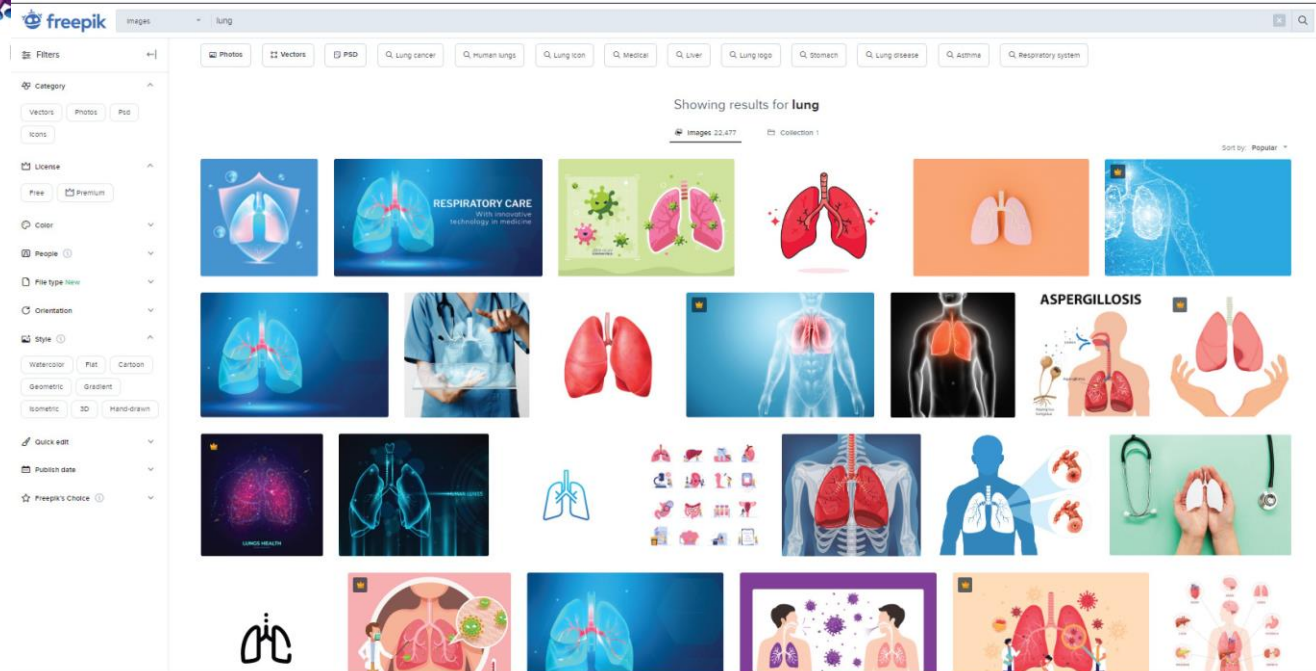
Bacteria with facial expressions Free Vector

You may also like

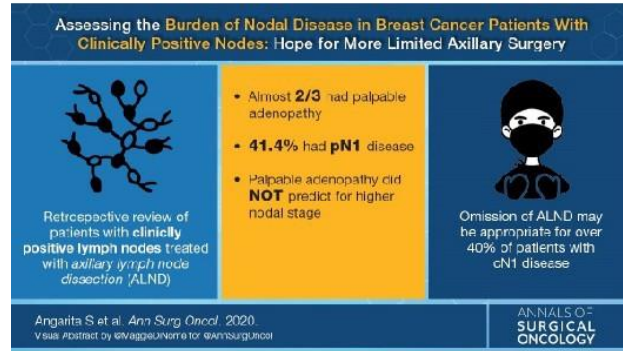


bacteria

<https://www.freepik.com/>

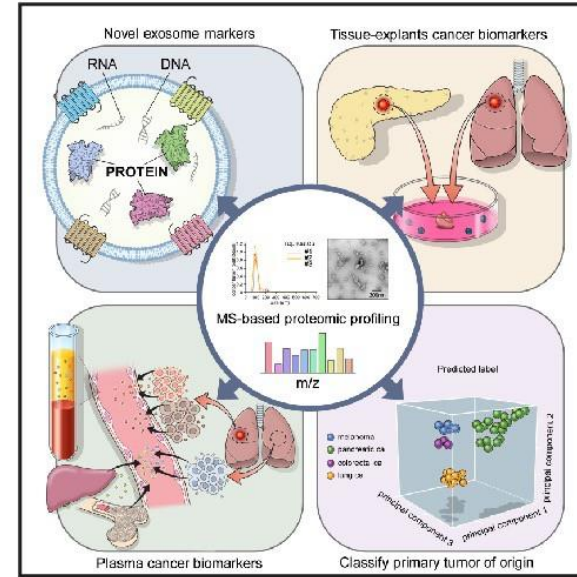


13.33 inch



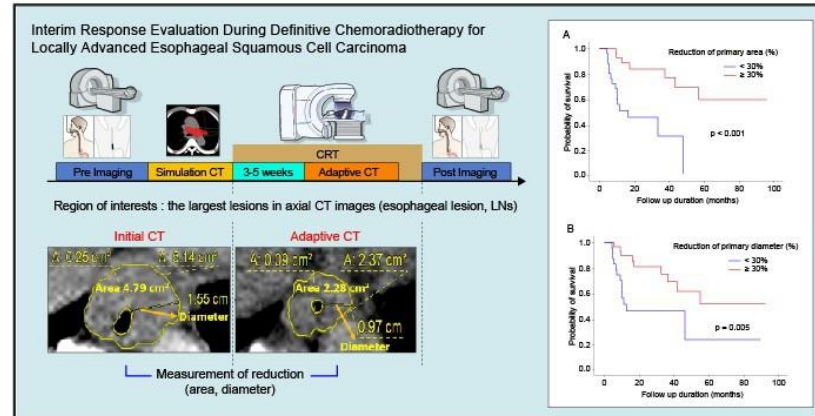
7.5 inch

5.5 inch



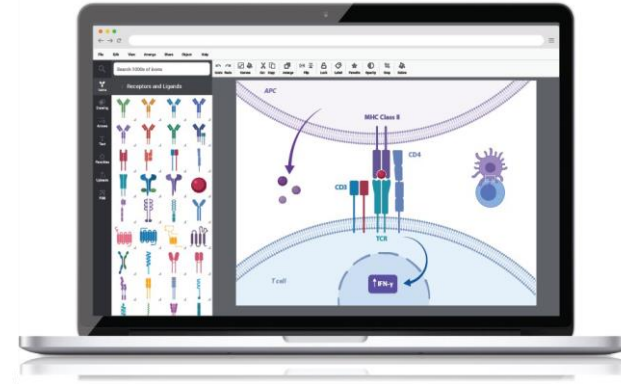
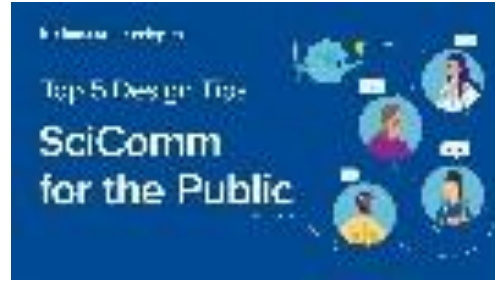5.5 inch

7.7778 inch (1100 pixels)


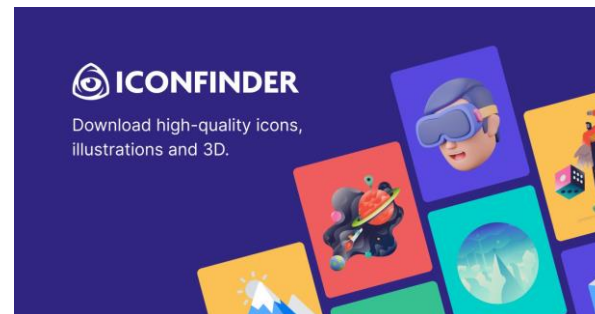
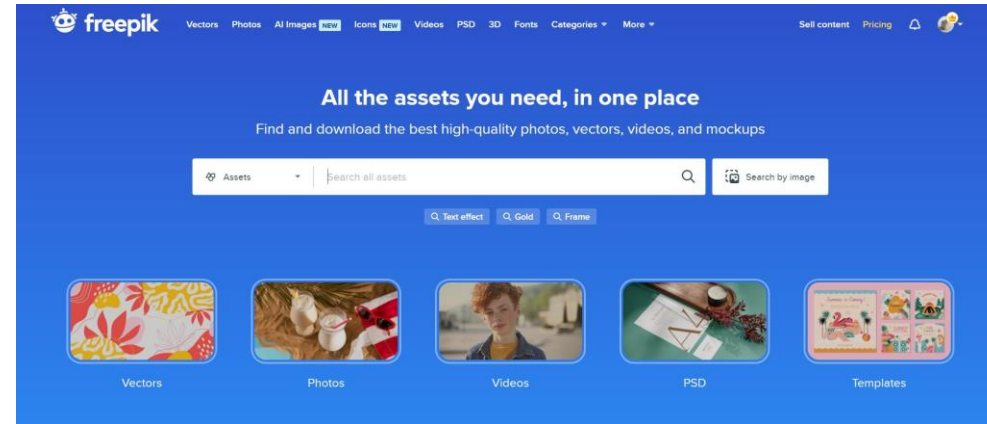


15.2778 inch (560 pixels)

biorender.com/



www.freepik.com/



<https://www.infography.co.kr/>

INFOGRAPHY



Clinical Sciences Medicine Surgery Basic Science Animal Cancer Children Medical and laboratory Etc Subscribe C/S

Search

SCI Journal Images

We designed more than 3000 SCI Journal Images

Navigation: Clinical Sciences, Medicine, Surgery, **Basic Science**, Animal, Cancer, Children, Medical and laboratory, Etc

Search

Filters: Anatomy, **Cell**, Microbiology, Physiology, Neuroscience

Grid of Anatomy images:

- Anatomy(819) 10,000원
- Anatomy(818) 10,000원
- Anatomy(817) 10,000원
- Anatomy(816) 10,000원**
- Anatomy(815) 10,000원
- Anatomy(814) 10,000원
- Anatomy(813) 10,000원
- Anatomy(812) 10,000원
- Anatomy(811) 10,000원
- Anatomy(810) 10,000원
- Anatomy(809) 10,000원
- Anatomy(808) 10,000원
- Anatomy(807) 10,000원
- Anatomy(806) 10,000원
- Anatomy(805) 10,000원
- Anatomy(804) 10,000원
- Anatomy(803) 10,000원
- Anatomy(802) 10,000원
- Anatomy(801) 10,000원

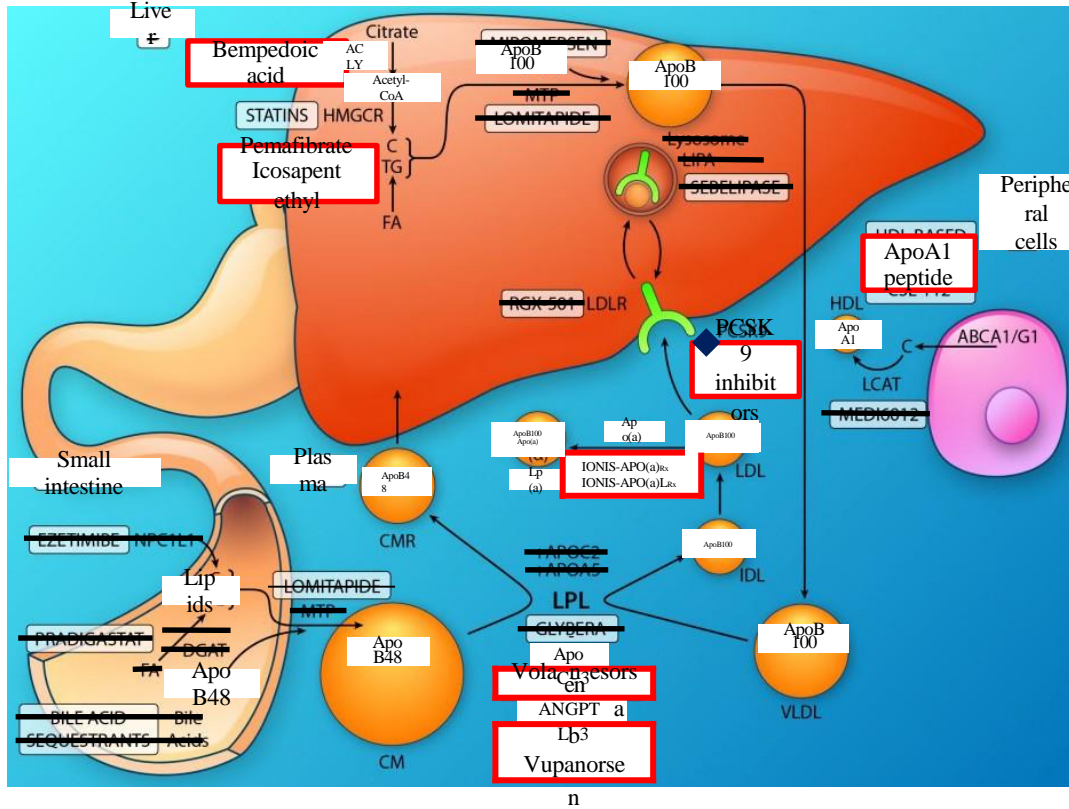
Navigation: Anatomy, **Cell**, Microbiology, Physiology, Pharmacology

Grid of Cell images:

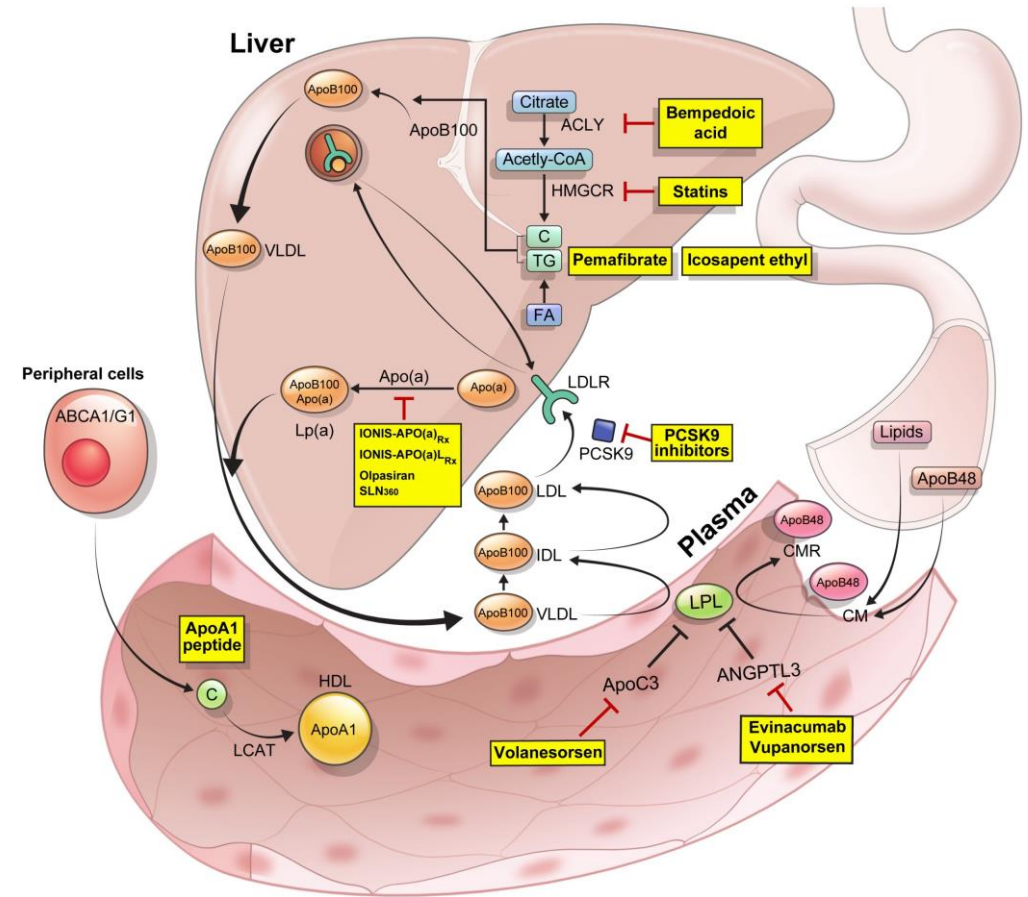
- Cell(421) 10,000원
- Cell(420) 10,000원
- Cell(419) 10,000원
- Cell(418) 10,000원
- Cell(417) 10,000원
- Cell(416) 10,000원
- Cell(415) 10,000원
- Cell(414) 10,000원
- Cell(413) 10,000원
- Cell(412) 10,000원
- Cell(411) 10,000원
- Cell(410) 10,000원
- Cell(409) 10,000원
- Cell(408) 10,000원
- Cell(407) 10,000원
- Cell(406) 10,000원
- Cell(405) 10,000원
- Cell(404) 10,000원
- Cell(403) 10,000원
- Cell(402) 10,000원
- Cell(401) 10,000원

*Me
병원, 의과
이미지를 전
이미지는 인
의학 분야

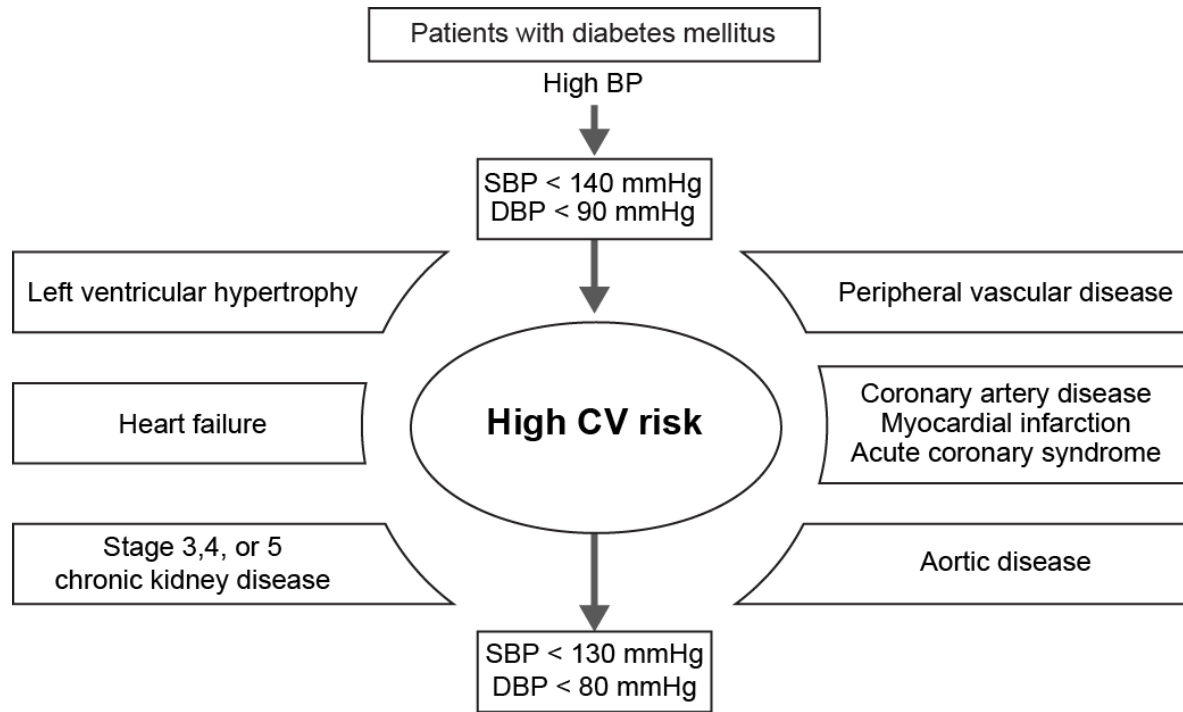
Before



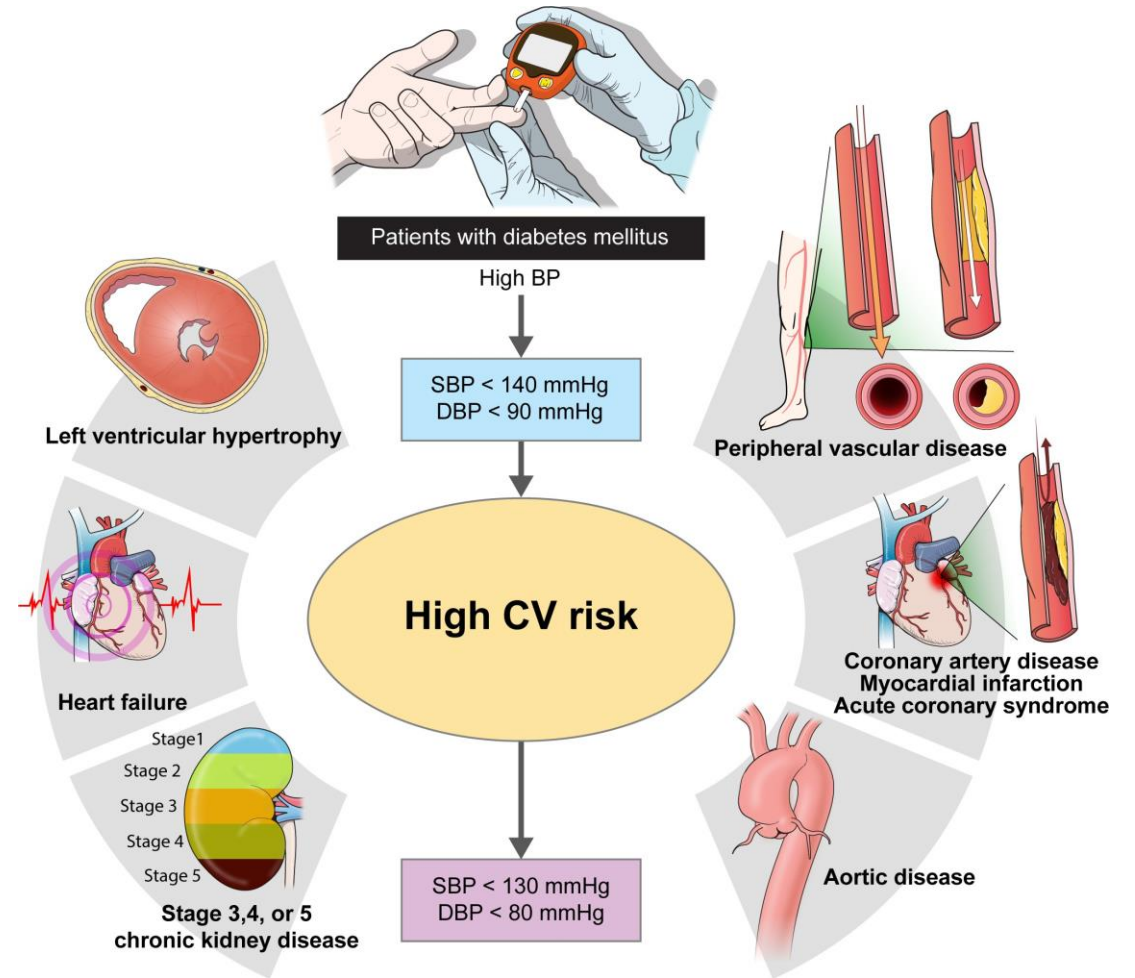
After



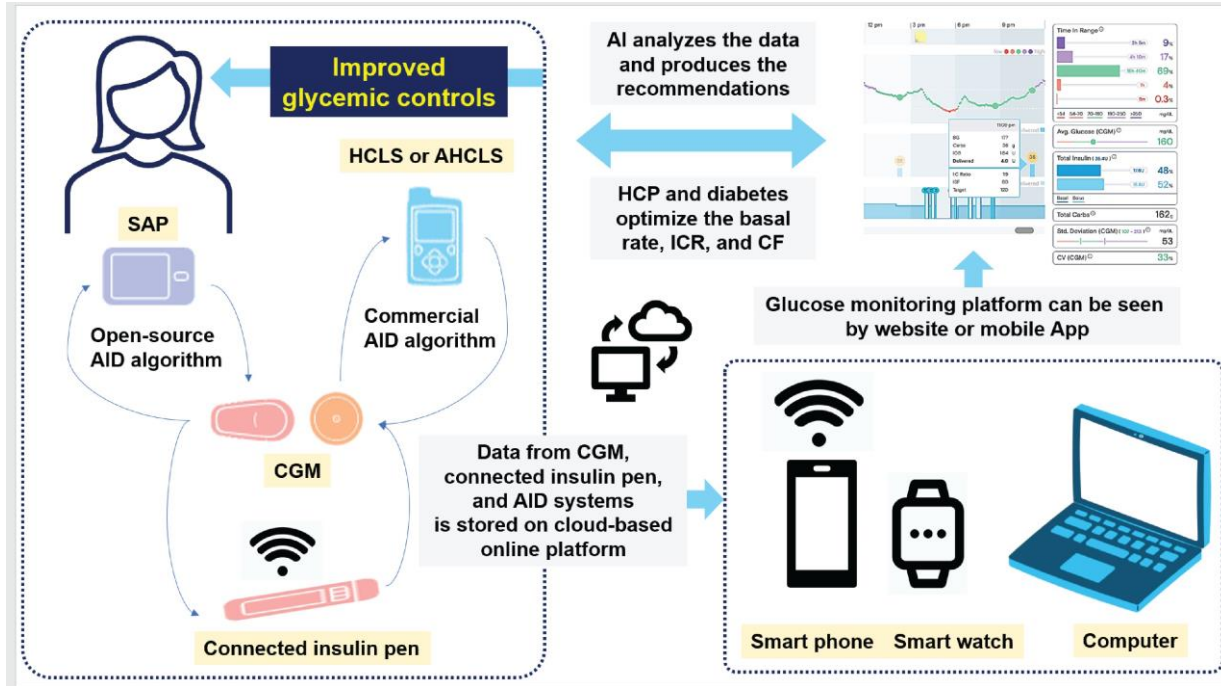
Before



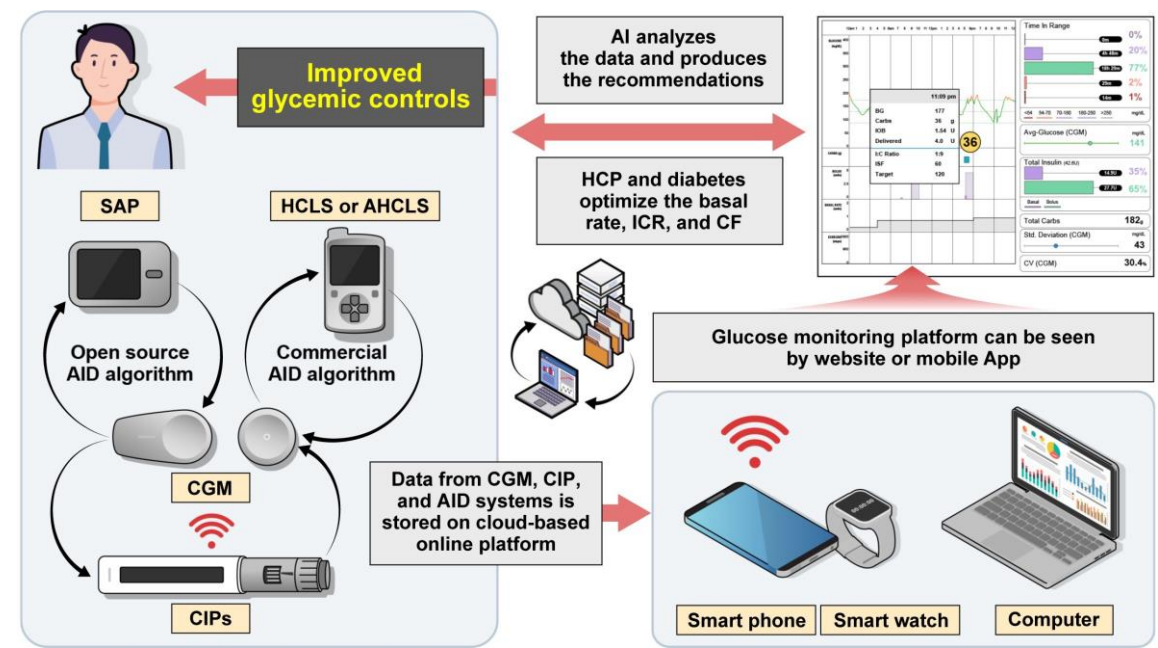
After



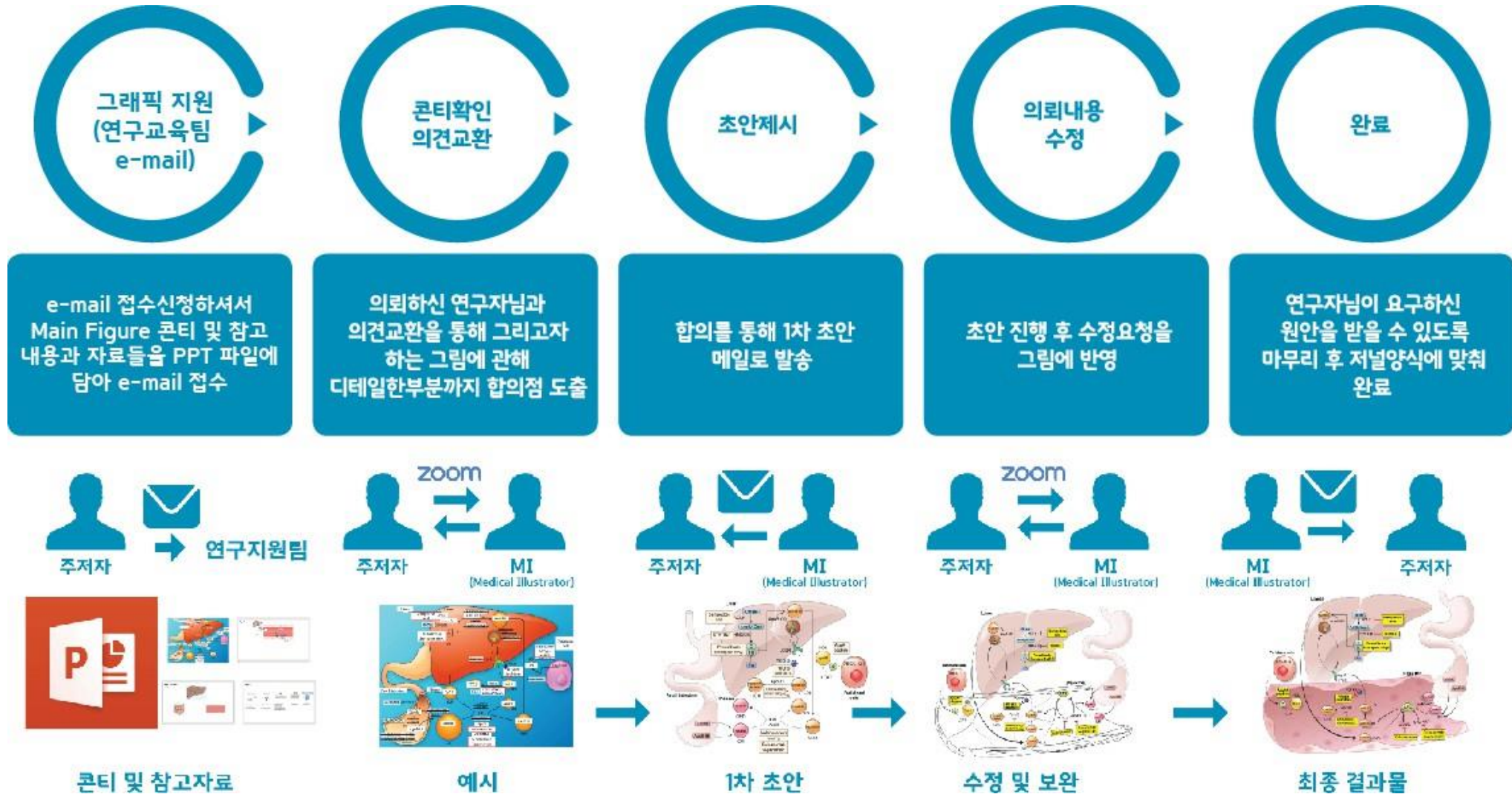
Before



After



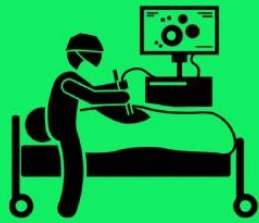작업 진행 과정



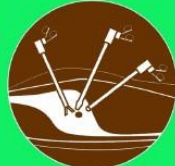Spotlight on Laparoscopy in the Surgical Resection of Locally Advanced Rectal Cancer Multicenter Propensity Score Match Study

Total n = 418 (LARC = 109 Vs NLARC = 109)

Conversion to open Surgery



LARC 4.6%

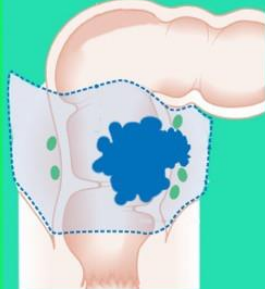

NLARC 1.8%



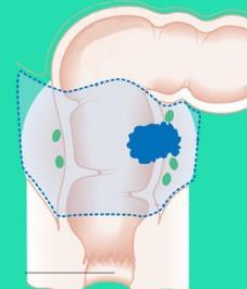
P = 0.445%

Circumferential resection margin (+CRM)



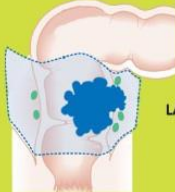LARC 9.2%

P = 0.284%

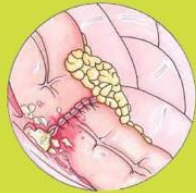

NLARC 4.6%

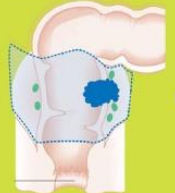Anastomotic Leak Rate



LARC 4.3%

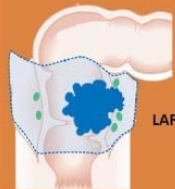

P = 0.670%




NLARC 2.3%

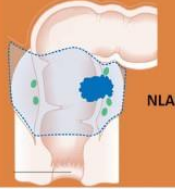
Complications: Clavien dindo III & IV



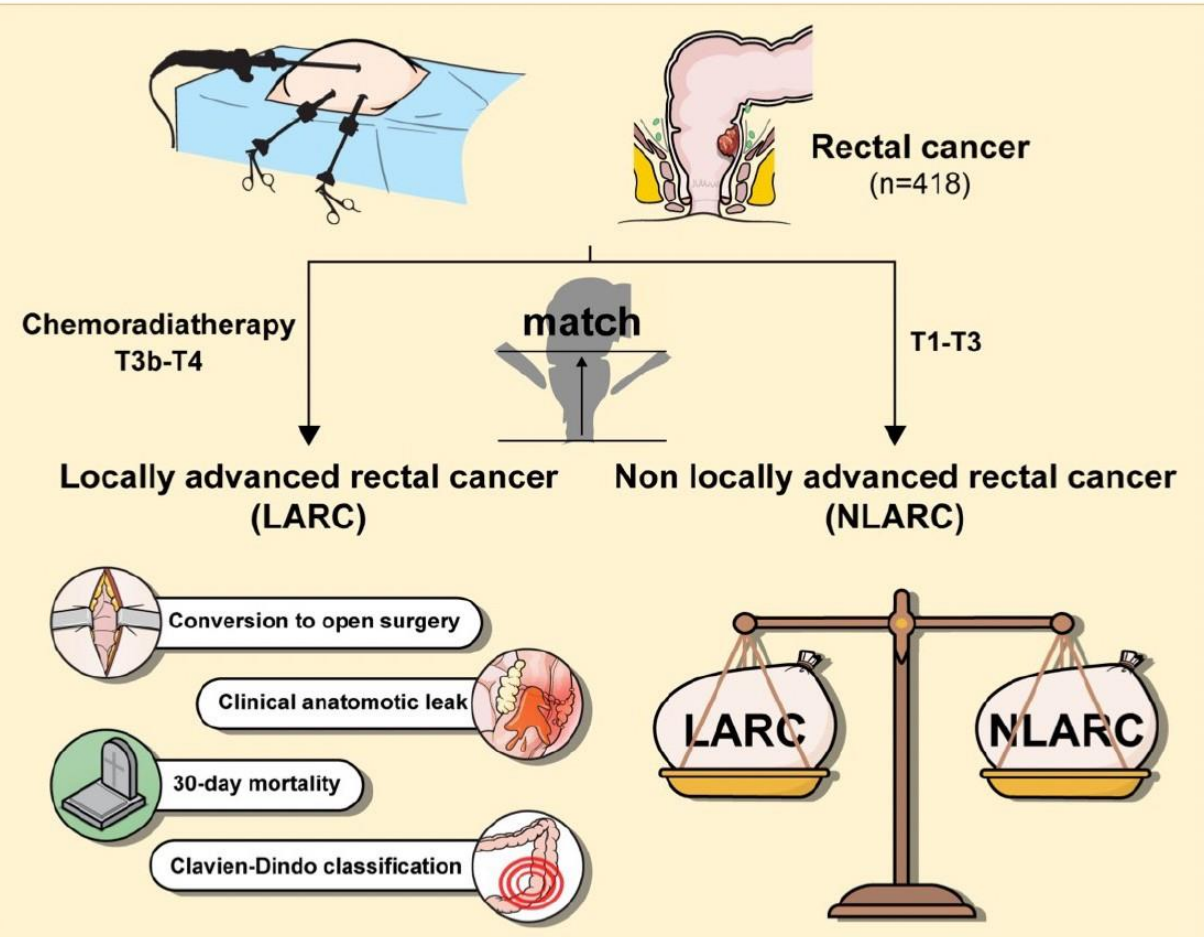
LARC 19.3%



P = 0.274 %



NLARC 13.8%



Colorectal surgical management of colitis induced by vasculitis in the absence of inflammatory bowel disease: a case report and literature review

Jessica A. Paynter^{1,2}, Kirby R. Qin^{3,4}, Georgia Seamer², Ruchira Fernando⁵, Janelle Brennan^{2,4}, Chun Hin Angus Lee¹

¹Department of General Surgery, Bendigo Health, Bendigo, VIC, Australia
²Monash University School of Rural Health Bendigo, Bendigo, VIC, Australia
³Department of Urology, Austin Health, Heidelberg, VIC, Australia
⁴Department of Urology, Bendigo Health, Bendigo, VIC, Australia
⁵Australian Clinical Laboratory Pathology, Bendigo, VIC, Australia

Colitis caused by vasculitis is a rare and poorly understood pathology. Little evidence exists on its clinical presentation, path to diagnosis, and surgical management. In this report, we present a case report and literature review. A healthy 20-year-old male patient presented with hemorrhagic colitis requiring total colectomy with end ileostomy. Pathological examination showed pancolitis with multiple ulcers, transmural inflammation, hemorrhage, and microvascular thrombosis. Extensive serological testing revealed elevated cytoplasmic antineutrophil cytoplasmic antibody (c-ANCA) and eosinophilia, leading to a diagnosis of eosinophilic granulomatosis with polyangiitis (EGPA) and vasculitis-induced colitis. A literature review was subsequently conducted. Nineteen studies were found documenting vasculitis-induced colitis in the absence of inflammatory bowel disease (IBD). Systemic signs of vasculitis, hemorrhagic colitis, and progression to fulminant colitis were present. Of all patients, 40.0% required colorectal surgery and 62.5% of those patients received a stoma; 25% underwent emergency surgery following failed immunosuppression. All cases relied on clinical correlation with serology and/or histopathology to reach a final diagnosis. We report a case of vasculitis-induced colitis caused by c-ANCA-positive EGPA. The review shows that vasculitis-induced colitis without IBD is an important differential that clinicians should be aware of in patients presenting with colitis.

Keywords: Colitis; Vasculitis; Colorectal surgery; General surgery

INTRODUCTION

Colitis is inflammation of the colon, which can be acute, self-limiting, or chronic. Colitis can be caused by a number of conditions, which are broadly subtyped into autoimmune, infections, isch-

emic, iatrogenic (e.g., diversion or radiation colitis), or microscopic. Vasculitis can cause ischemic colitis due to the involvement of mesenteric arteries and veins (or even smaller vessels) [1].


Colitis is a core component of inflammatory bowel disease (IBD). IBD includes 2 conditions: ulcerative colitis (UC) and Crohn disease (CD). Particularly in UC, colitis can acutely manifest with fulminant colitis and toxic megacolon [2, 3]. An acute colitis flare is commonly managed with anti-inflammatory and immunosuppressive agents, with potential progression to surgical management if the disease progresses to fulminant colitis or toxic megacolon [4]. As IBD is believed to be an immune-mediated inflammatory disease, patients with IBD have an elevated risk of developing autoimmune diseases, including vasculitides [5]. Many studies have explored the propensity for vasculitides in IBD to cause colitis independently [6–9]. Behçet disease is another

Received: Aug 19, 2022 • Revised: Sep 24, 2022 • Accepted: Oct 8, 2022
Correspondence to: Jessica A. Paynter, MBBS (Hons), BMedSc (Hons)
Department of General Surgery, Bendigo Health, 100 Barnard St, Bendigo, VIC 3500, Australia
Email: jess.paynter@monash.edu
ORCID: https://orcid.org/0000-0002-5888-7391

© 2022 The Korean Society of Coloproctology

This is an open-access article distributed under the terms of the Creative Commons Attribution Non-Commercial License (<https://creativecommons.org/licenses/by-nc/4.0/>) which permits unrestricted non-commercial use, distribution, and reproduction in any medium, provided the original work is properly cited.

ACP New Design from Aug 2023



Total neoadjuvant therapy for rectal cancer: evidence and challenge

Suk-Hwan Lee

Department of Surgery, Kyung Hee University Hospital at Gangdong, Kyung Hee University College of Medicine, Seoul, Korea

Recent advances in the management of rectal cancer have dramatically changed the clinical practice of colorectal surgeons because the main focus of rectal cancer treatment has changed from sphincter-saving to an organ-preserving strategies. Modifying the delivery of systemic chemotherapy to improve patients' survival is another progress in colorectal cancer management, known as total neoadjuvant therapy (TNT). TNT is a new strategy used by colorectal surgeons to improve the quality of life and survival of patients after treatment. TNT poses limitations or obstacles, such as overtreatment issues in patients with stage I rectal cancer. However, considering the quality-of-life issues in patients with low-lying rectal cancer necessitating a permanent colostomy, the indication for TNT will be expanded. This review summarizes the recently conducted clinical trials and foresees future perspectives on TNT.

Keywords: Rectal neoplasms; Consolidation chemotherapy; Induction chemotherapy; Neoadjuvant therapy; Total neoadjuvant therapy

INTRODUCTION

Advanced rectal cancers were traditionally treated with neoadjuvant chemoradiation therapy (nCRT) followed by total mesorectal excision (TME) and postoperative adjuvant chemotherapy [1, 2]. This multimodal approach significantly improved local control; however, overall survival did not improve, mainly due to distant metastasis after the surgery [3]. Marginal or poor overall survival resulted from micrometastatic disease during the waiting period after the nCRT to surgery and poor compliance with postoperative adjuvant chemotherapy.

Recent evidence has shown a good prognosis when patients achieve pathologic complete response (pCR) after nCRT [4, 5]. The current rectal cancer management should be extended to achieve more pCR and apply the organ-preserving strategy be-

yond the sphincter-preserving surgery because it harbored many disadvantages, such as low anterior resection syndrome, sexual and voiding difficulties, and permanent colostomy [5, 6].

Various approaches have been tested to improve the survival of rectal cancer patients and have resulted in promising outcomes. A new treatment strategy named total neoadjuvant therapy (TNT), consists of chemotherapy given before or after the CRT to control micrometastatic disease earlier and improve compliance with chemotherapy.

The year 2022 will be a landmark year for the treatment of rectal cancer because the mainstream of rectal cancer management has been changed from nCRT to TNT. The National Comprehensive Cancer Network (NCCN) guideline endorsed the TNT strategy for the circumferential resection margin (CRM) threatening and CRM-negative tumors in the 2022 guideline [7]. These dra-

Received: April 13, 2023; Revised: June 28, 2023; Accepted: June 28, 2023

Correspondence to: Suk-Hwan Lee, MD

Department of Surgery, Kyung Hee University Hospital at Gangdong, College of Medicine, Kyung Hee University, 892 Dongnam-ro, Gangdong-gu, Seoul 05278, Korea
Email: leeshrd@khu.ac.kr

© 2023 Korean Society of Coloproctology

This is an Open Access article distributed under the terms of the Creative Commons Attribution Non-Commercial License (<http://creativecommons.org/licenses/by-nc/4.0/>) which permits unrestricted non-commercial use, distribution, and reproduction in any medium, provided the original work is properly cited.

International Society of University Colon and Rectal Surgeons survey of surgeons' preference on rectal cancer treatment

Audrius Dulskas^{1,2}, Philip F. Caushaj³, Domas Grigoravicius², Liu Zheng⁴, Richard Fortunato⁵, Joseph W. Nunoo-Mensah⁶, Narimantas E. Samalavicius^{2,7,8}

¹Department of Abdominal and General Surgery and Oncology, National Cancer Institute, Vilnius, Lithuania

²Institute of Clinical Medicine, Faculty of Medicine, Vilnius University, Vilnius, Lithuania

³Department of Surgery, University of Connecticut School of Medicine and Hartford Hospital, Hartford, CT, USA

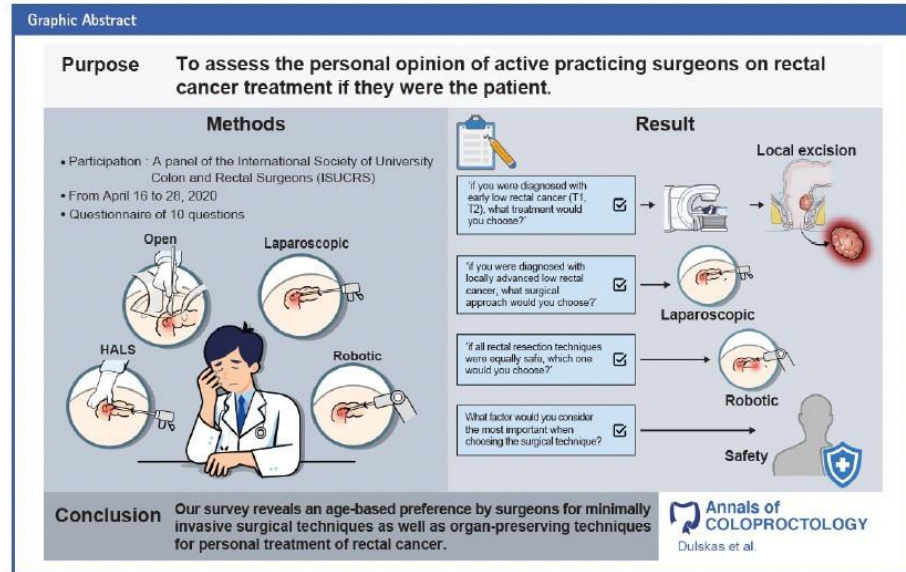
⁴Department of Colorectal Surgery, National Cancer Center, National Clinical Research Center for Cancer/Cancer Hospital, Chinese Academy of Medical Science and Peking Union Medical College, Beijing, China

⁵Department of Colorectal Surgery, Allegheny General Hospital, Pittsburgh, PA, USA

⁶Department of Colorectal Surgery, King's College Hospital Foundation NHS Trust, London, UK

⁷Department of Surgery, Klaipeda University Hospital, Klaipeda, Lithuania

⁸Health Research and Innovation Science Centre Faculty of Health Sciences, Klaipeda University, Klaipeda, Lithuania



Received: April 9, 2022; Revised: May 18, 2022; Accepted: May 20, 2022

Correspondence to: Audrius Dulskas, MD, PhD

Department of Abdominal and General Surgery and Oncology, National Cancer Institute, Santariskiu St, Vilnius 08406, Lithuania

Email: audrius.dulskas@gmail.com

© 2023 Korean Society of Coloproctology

This is an Open Access article distributed under the terms of the Creative Commons Attribution Non-Commercial License (<http://creativecommons.org/licenses/by-nc/4.0/>) which permits unrestricted non-commercial use, distribution, and reproduction in any medium, provided the original work is properly cited.

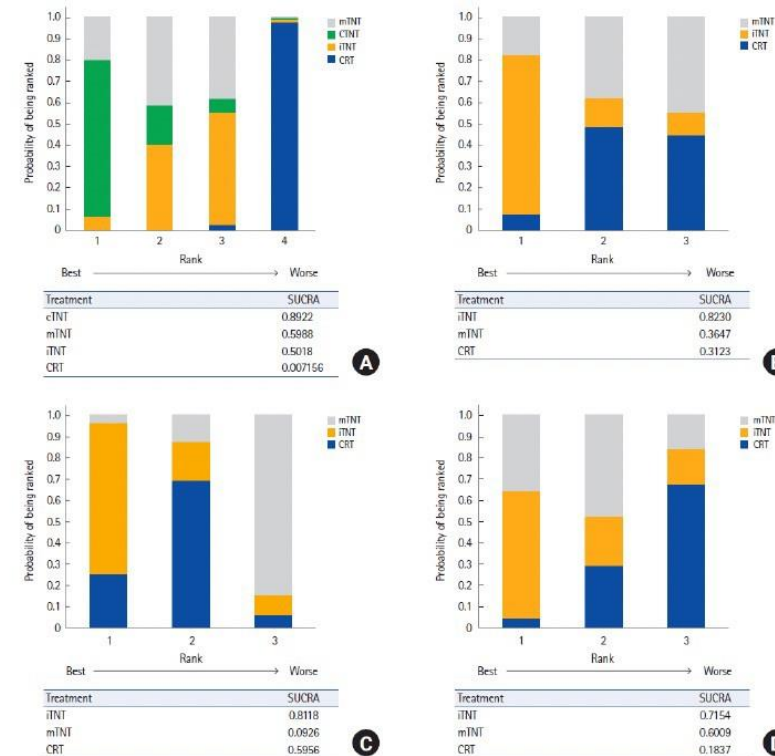


Fig. 4. Ranking plots for the efficacy of the comparison of outcomes among different neoadjuvant regimens. (A) Pathologic complete response. (B) Overall survival. (C) Local recurrence rate. (D) Metastasis rate. SUCRA, surface under the cumulative ranking curve. CRT, chemoradiotherapy; TNT, total neoadjuvant treatment; cTNT, long-course CRT (50–54 Gy) followed by consolidation chemotherapy; iTNT, induction chemotherapy followed by CRT (50–54 Gy) and capecitabine; mTNT, short-course radiotherapy (25 Gy) followed by consolidation chemotherapy.

Methodological quality

The patients or researchers in the studies included in the meta-analysis were not blinded in any of the publications. The details of randomization and allocation into groups were not available in some studies. A summary of the RoB is demonstrated in Fig. 9. The RoB for all enrolled studies is shown in Fig. 10.

DISCUSSION

The combination of CRT and optimal surgical techniques has significantly improved the treatment outcomes of patients with non-

metastatic cancer of the mid and low rectum. This combined approach enables local control of disease to be achieved in most patients with stages II to III rectal cancer, although the 5-year OS rate in stage III does not exceed 70% to 76%, due to distant metastases. This fact confirms the importance of early administration of systemic treatment [1, 26, 27].



Standard protocols for the treatment of patients with stage III rectal cancer recommend systemic chemotherapy in the postoperative setting [28], though these recommendations are based on the results of clinical studies of adjuvant chemotherapy for colon cancer [29, 30]. The role of systemic chemotherapy in the treat-



Annals of COLOPROCTOLOGY



Let's visit "ACP Photo Booth" in the Grand Hall

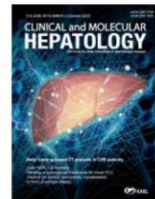



Review | May 25, 2023 |

The evolving role of lenvatinib at the new era of first-line hepatocellular carcinoma treatment


Landon L. Chan, Stephen L. Chan
Clin Mol Hepatol. 2023;29(4):909-923.

Emergence of multi-targeted kinase inhibitors (MTIs) and immune checkpoint inhibitors (ICI) have changed the landscape of management in hepatocellular carcinoma (HCC). Combination therapy involving ICI has superseded sorafenib as the...




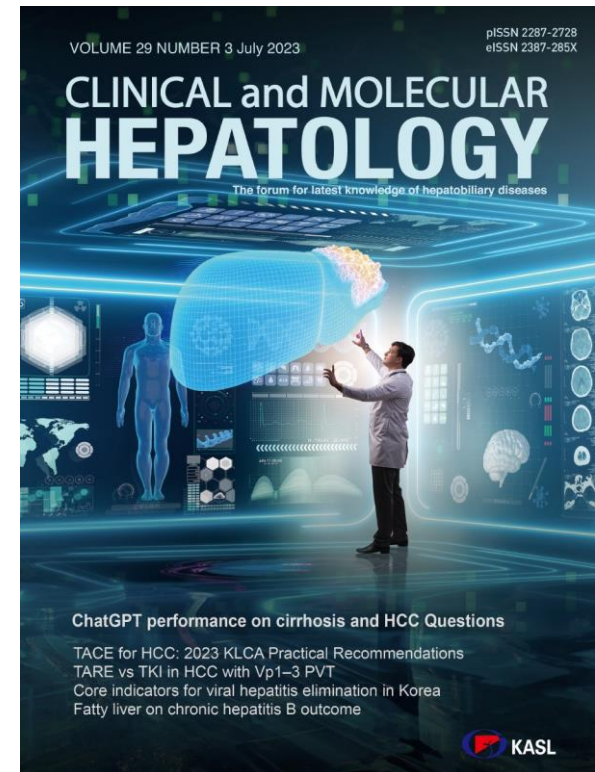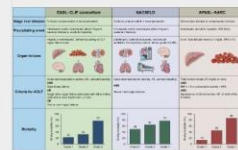
Clinical and Molecular Hepatology

Print ISSN: 2287-2728
Online ISSN: 2287-285X

Submit Your Manuscript 

Snapshot

Acute on chronic liver failure in cirrhosis



studiomid.com
studiomid@outlook.com
artanato@yuhs.ac

감사합니다

